GUIDELINES FOR HISTOPATHOLOGICAL EVALUATION OF BOVINE CORNEAS AS AN ENDPOINT OF THE BOVINE CORNEAL OPACITY AND PERMEABILITY (BCOP) ASSAY

TABLE OF CONTENTS

1. Depth of Injury as a Predictor of Degree and Duration of Ocular Injury 3

2. Application of histological assessment to the determination of ocular irritation potential 5

3. Overview of the Histology Procedures Used at IIVS 6

3.1 Corneal Accession Numbers 6
3.2 Fixation of the Corneas 6
3.3 Preparation of the Slides 6
3.4 Recording Observations 11
3.5 Preparation of the Photomicrographs 12

4. Evaluating the Cornea Histology 8

4.1 Evaluation of the Corneal Sections (Overview) 8
4.1.1 Comparison of Human, Rabbit, and Bovine Corneas 12
4.1.2 Evaluating the Negative Control-Treated Corneas 14
4.1.3 Evaluating the Corneal Lesions 14

4.2. A short compendium of micrographs to illustrate negative control-treated (normal) and select lesions in bovine corneal tissue 16
4.2.1 Negative Control Corneas 17
4.2.2 Epithelial Damage 19
4.2.3 Stromal Lesions 25
4.2.4 Endothelial Cell Lesions 27

5. References 30

1. Depth of Injury as a Predictor of Degree and Duration of Ocular Injury

Brief Introduction – Bovine Corneal Opacity and Permeability Assay

The Bovine Corneal Opacity and Permeability (BCOP) assay was developed by Drs. Pierre Gautheron (Gautheron, Dukic et al. 1992) and Joe Sina (Sina, Galer et al. 1995) to address ocular irritation potential of pharmaceutical intermediates for industrial hygiene purposes. The assay measures changes in corneal opacity (determined by changes in light transmission) and permeability to fluorescein (measured by increases in permeability to fluorescein) as a result of chemical insults. The opacity and permeability values are used to calculate an *in vitro* score, in order to evaluate the ocular irritation potential. The method is now widely applied across industries and chemical/formulation classes. For many, if not most, of these chemical/formulation classes, the mode of action(s) of the test material is generally known. Membrane lysis, protein coagulation, and saponification are common modes of action that lead to ocular irritation. In our experience, the opacity and permeability endpoints have been able to identify the epithelial and stromal changes associated with this type of damage. Endothelial cell damage has been harder to assess through permeability changes unless the epithelium is largely destroyed, where the passage of fluorescein is greatly enhanced (data unpublished). However, the prediction of ocular irritation from chemicals that react with nucleic acids, mitochondrial proteins, or other cellular targets, that do not lead to immediate loss of cellular integrity (particularly in the epithelium), has proven more difficult using only the opacity and permeability endpoints. This difficulty was evident in the results of the EC/HO study where certain strong irritants were under-predicted by the *in vitro* score. It was this study that prompted us to begin the active examination of histological changes in conjunction with the primary opacity and permeability measurements (Curren, Evans et al. 2000).

With the addition of the histological assessment of depth of injury, the BCOP would seem to address most of the requirements proposed by Drs. Maurer and Jester in their 2002 publication "Extent of Initial Corneal Injury as the Mechanistic Basis for Ocular Irritation: Key Findings and Recommendations for the Development of Alternative Assays" (Maurer, Parker et al. 2002).

- The BCOP assay uses a three-dimensional tissue that contains the three layers of interest in the cornea.
- The corneal tissue is very much alive using the standard organ culture procedures of the BCOP protocol, and can be maintained with repeated medium changes for up to 24 hours.
- Cytotoxicity and structural damage to the three layers of the cornea are measured with several, complementary endpoints.
- One can determine initial injury after different periods of exposure and can follow the progression of damage over the first 20+ hours after exposure.

For ease in understanding the mechanistic basis of the BCOP assay, a table (Table 1) has been compiled describing the events that are commonly considered to occur during eye irritation. Those events that are modeled (or are closely related) by the BCOP assay are indicated by a Y (yes) indication.

It can be seen that the BCOP assay closely models not only most of the initial stages of interaction of an eye irritant with the cornea, but also some of the more distal occurrences in eye irritation such as gross tissue changes in the corneal stroma. However, the short time period that the cornea can be kept in organ culture limits the amount of recovery, if any, which may occur. Again, if the hypothesis of Jester, Maurer, and others that initial area and depth of injury is predictive of time to, and extent of recovery, then the measurements made by the BCOP assay may have a relationship to recovery as well.

Table 1 Summary of events involved in chemical-induced eye irritation *in vivo.* Text in italics represents irreversible responses.

Events involved in chemical-induced eye irritation	Modeled by the BCOP assay?
Chemical interaction with tear film (Klyce and Beuerman 1988; Hackett and McDonald 1994)	N
Chemical binding to the conjunctival epithelium (Hogan and Zimmerman 1962; Hackett and McDonald 1994)	Y
Adhesion molecules compromised (Farquhar and Palade 1963; Van Meer, van Hof et al. 1992; Katahira, Sugiyama et al. 1997)	Y
Corneal epithelium damage (Dua, Gomes et al. 1994)	Y
• Inhibition of receptor-mediated membrane transport (Dearman, Cumberbatch et al. 2003)	Y
• Compromise of cell membrane integrity of upper corneal epithelium (Dua, Gomes et al. 1994; Hackett and McDonald 1994; Maurer and Parker 1996)	Y
• Cell membrane lysis of all corneal epithelium layers (Hackett and McDonald 1994)	Y
Hydration of corneal stroma (Hackett and McDonald 1994)	Y
Cross-linking of proteins in corneal stroma (Butler and Hammond 1980; Eurell, Sinn et al. 1991; Chan and Hayes 1994)	Y
Erosion of corneal stroma (Baldwin, McDonald et al. 1973; Hackett and McDonald 1994; Maurer and Parker 1996)	Y
Cell damage to corneal epithelium and limbus (Jacobs and Martens 1990; Wilhelmus 2001)	Y
Dilation and increased lymphatic leakage from scleral vasculature (Hackett and McDonald 1994)	N
Stimulation of nerve endings, i.e., enhanced blinking, tearing (Chan and Hayes 1994)	N
Erosion of nerve endings in cornea and sclera (Butler and Hammond 1980; Klyce and Beuerman 1988; Araki, Ohahsi et al. 1994)	N
Duration of response, *i.e.*, length of time cell responses deteriorate. Duration of response covers the effects of reactive chemicals which can cause coagulation, saponification, that are effects which develop and increase over time. (Hubert 1992; Maurer and Parker 1996)	Partially
Recovery from response, *i.e.*, length of time for cell responses to return to control levels (Hubert 1992)	N

When conducting BCOP studies at the Institute for In Vitro Studies, Inc. (IIVS), histology may be included in the study protocol for several reasons. Some clients wish to understand the tissue changes associated with exposure to the products under study. In other cases, the depth of injury associated with the new formulation will be compared to the depth of injury induced by a reference material(s). Clients are strongly encouraged to include concurrent benchmark formulations to facilitate interpretation of the study. In addition, positive and negative control corneas are always used (Cuellar, Merrill et al. 2002). The positive controls provide a measure of reproducibility of the test system and assay execution, while the negative controls provide the baseline against which histological changes are compared. This approach is common in final product testing or when the study is intended for submission to a regulatory agency (e.g., USEPA). The histology allows the agency reviewer to more completely use the data from the reference article(s) to determine the labeling requirements for the new formulation. When formulations contain reactive chemicals (e.g., peroxides, bleaches, etc.) where immediate changes in corneal transparency or barrier function may not be evident, histology is definitely recommended. (Maurer, Molai et al. 2001) have shown that oxidizing agents induce a delayed toxicity *in vivo* and act more profoundly on the keratocytes. Our experience has shown that peroxide-containing formulations require histological assessment to elucidate the full depth of injury (Swanson, White et al. 2003). New chemistries, where the mode of action cannot be predicted or "reactive chemistry" is expected, require special handling (discussed below), including histology (Curren, Evans et al. 2000).

2. Application of histological assessment to the determination of ocular irritation potential

The results of a histological evaluation may be used in several ways depending on the needs of the study sponsor. In some cases, it is used to confirm the absence of tissue damage beyond that detected by the opacity and permeability scores. In other cases, it is helpful to understand the types of lesions that a material might induce. In some studies, we have compared the depth of injury induced by a product concentrate and then the mitigation produced by dilution. This approach can be used to model the ocular irritation potential of properly-prepared end-use dilutions (as specified by the label) as well as the ocular irritation potential for more concentrated solutions (produced by those who do not follow label instructions). The most common application, in our experience, is to compare depth and degree of injury in a benchmark formulation(s) with the changes in the new formulation(s). In this way, all three endpoints (opacity, permeability, and histological changes) are used to make the final assessment of ocular irritancy potential. This is how much of final product safety assessment is conducted and how studies submitted to the Office of Pesticide Programs, USEPA for product registration have been performed.

It should be understood that a stand-alone, quantitative prediction model for the translation of depth of injury observations (by themselves) to a predicted degree and duration of ocular irritation in the rabbit has not been completed. Where a prediction of irritation potential in the rabbit is desired by the study sponsor, the depth and degree of injury induced by the test material is compared to the depth and degree of injury to the benchmark(s) materials.

Not all of the BCOP studies require histological evaluation. Where the mode of action of the test article on the cornea is well understood (e.g., surfactant formulations, highly acidic

and alkaline materials, etc.), the use of the opacity a permeability measurements typically provide sufficient predictive capacity to determine ocular irritation potential.

3. Overview of the Histology Procedures Used at IIVS

3.1 Corneal Accession Numbers

Each cornea is assigned a unique sequential number. The accession number, test article or control designation, exposure time, harvest date, cornea number (from that day's assay) and any needed comments are recorded on the histology record. A copy of the data is placed in the study notebook and histology logbook.

3.2 Fixation of the Corneas

The corneas are fixed after the completion of the fluorescein penetration step of the BCOP assay. In-house evaluation has shown that the fluorescein exposure does not impact tissue morphology. In addition, fixing the corneas at this step allows the histological evaluation to be performed on the same corneas from which the opacity and permeability values were taken. Once the posterior chamber of the corneal holder has been sampled, the remaining fluids are removed and the chamber dismantled. Each cornea is placed into a tissue cassette that has been pre-labeled with its accession number (as above). The cassette is fitted with a "histology sponge" to help protect the endothelial surface. The cornea will be placed onto the sponge with the epithelium facing up. Care is taken to prevent the cornea from drying during the transfer process. The cassette is closed and immersed in 10% neutral buffered formalin. It is important to assure that the tissue is fully submerged in the formalin. Approximately 20 cassettes are fixed in a volume of 300 mL. Corneas should be fixed at room temperature for at least 24 hours before processing.

Whereas the use of a Davidson's fixative is frequently recommended for the rapid fixation of whole globe eye tissue, in-house comparisons of excised bovine corneas fixed in Davidson's fixative and 10% neutral buffered formalin have shown that the latter has provided suitable fixation of the tissues.

3.3 Preparation of the Slides

Corneas are trimmed, embedded, sectioned and stained by a qualified histology laboratory. The following general guidance is provided to the histology laboratory:

The actual size of the cornea and the treatment area are shown below. The center shows the area treated and the area of interest for histological examination.



Cornea shown during disassembly

The fixed corneas are transferred to the histology laboratory. Placement paperwork will be sent with the corneas. Upon receipt by the histology lab, the samples will be received into their tissue accession system.

The corneas may be trimmed to remove some of the excess scleral tissue outside of the outer crush zone if necessary; however, the cornea will be infiltrated whole. Before the corneas are placed on the tissue infiltration machine, a second sponge will be placed on the anterior (epithelial) surface of the cornea. This second sponge is intended to reduce the chances of tissue warping during infiltration. Corneas are always mounted in the cassette at IIVS with the anterior surface facing the upper lid. Infiltration will proceed according to the current SOP. Elevated temperatures should not be used with the infiltrating solvents.

Once infiltrated with paraffin, the cornea will be bisected so that the two halves of the cornea can be embedded in the same block. The cornea will have some wrinkles and so it is often helpful to cut across the wrinkles (if they fall in a particular orientation) so that a good cross section can be obtained when the tissue is sectioned.

Bisected cornea in paraffin block

The microtome cuts must produce as close to true cross sections (anterior to posterior) of the cornea as possible. The true cross section allows us to accurately measure increases in the thickness of the corneas (swelling as a result of test article exposure) relative to the thickness of the negative control-treated corneas. Large, deep molds must be used and great care in orienting the tissue is required. The two halves of the cornea are placed with the cut side down in the mold and aligned vertically and with their long axis in parallel with the long axis of the mold.

If the tissue is too long to fit into the mold, the outer edges (shown as the dark outer area above) may be trimmed. Ideally, one would like to see some of the dark “crushed” tissue in the section so as to be assured that one is evaluating the whole cross section of the cornea. Having the two tissue strips oriented in parallel along the long axis of the slide (once they are cut) makes scoring much easier.

Sectioning the tissue requires that the area damaged by the bisecting cut be trimmed away (with the microtome) so that the artifacts introduced by the cutting are not mistaken for changes associated with the test material exposure. The sections must include the full cross section of the cornea (epithelium, stroma, and endothelium). The corneal stroma is quite delicate and prone to artifacts from over-stretching of the sections on the water bath. In addition, over-stretching will induce breaks between the epithelium and stroma that might be mistaken for test article-induced damage.

4. Evaluating the Corneal Histology

4.1 Evaluation of the Corneal Sections (Overview)

The goal of the histopathology is to determine whether any changes from the control corneas are evident, and to determine the nature, depth and degree of the observed lesions within the treated corneas. The three tissue layers of the cornea are evaluated for lesions. Typically, the evaluations are conducted top-down, starting with the upper epithelium and progressing through the epithelial layers, through the stroma, and down to the corneal endothelium. Since test materials are applied topically on the outer corneal epithelium, the top-down evaluation follows the potential for lesions to occur dependant upon the penetration of the test chemical into the cornea, and the potential for toxic effects to be induced. In some cases, quite evident or notable changes are observed in the treated corneas. For example, gross changes or erosion of the corneal architecture, whether limited in depth of injury or as a full corneal thickness injury would be readily apparent. Other lesions may be a bit more subtle, and may simply be limited to changes in nuclear staining, perhaps as an apoptotic event. In such cases, these changes may be expected to result in downstream loss of corneal function, which may not be evident by the opacity and permeability endpoints in the standard short-term BCOP assay. Certain lesions are characteristic of severe irritants. These include necrosis or pyknosis of the keratocytes in the deep stroma (below mid depth) and loss of functional endothelium across the majority of the cornea. The loss of functional endothelium is reflected in the presence of collagen matrix vacuolization directly above Descemet's Membrane. Although, the slides are evaluated for rather subtle changes compared to what one might expect to see from an eye treated in the whole animal. This is because we are looking for the early events (tissue/cellular changes) that would be associated with the initiation of subsequent inflammatory reaction.

4.2 Evaluation of Quality and Acceptability of the Corneal Sections

Slides are normally stained with hematoxylin and eosin (H&E) although other stains may be requested. Positive and negative control corneas from each trial are processed with the relevant test article-treated corneas as a common process batch. The histology of the negative control corneas may thus be used to evaluate the quality/acceptability of the slides within the processing batch. Prior to conducting the evaluation of test article-induced histopathology, the quality of the H&E stained corneal sections must be evaluated, so that the pathologist can recognize the nature and degree of the artifacts. It is important to distinguish between test article-induced changes and artifacts of handling or processing. To this end, the negative control slides are used to detect artifacts at the batch level. They are also used to assess "normal" staining (degree of hematoxylin or eosin in each layer/cell type), tissue architecture and thickness. The following photographs are of negative control (DIH_20) treated corneas.

In the ideal, the corneal sections are prepared as true cross sections rather than tangential sections. However, some fraction of the sections (or portions of a section) will not be true cross sections and so the overall thickness and tissue architecture will be distorted from the ideal. There may also be some fields in a section that are tangential even when most of the section is a good cross section. In control or minimally damaged corneas, stromal thickness provides a good indication of how true the cross section is. In addition, the thickness of

Descemet's Membrane may provide a good measure of a true cross section. The Descemet's Membrane in a good section of a control cornea can be used to compare with treated corneas. This measure can be especially helpful in sections of treated corneas where collagen matrix vacuolization and stromal swelling are evident. It should be remembered, however, that Descemet's Membrane increases in thickness with age of the donor and so corneas from older cattle will have thicker membranes. In a true cross section, the endothelium is quite thin. The endothelium will be thicker in tangential sections. Where the tissue has been poorly prepared (e.g., overly trimmed or poorly embedded), the epithelium, stroma and Descemet's Membrane may appear very thick.

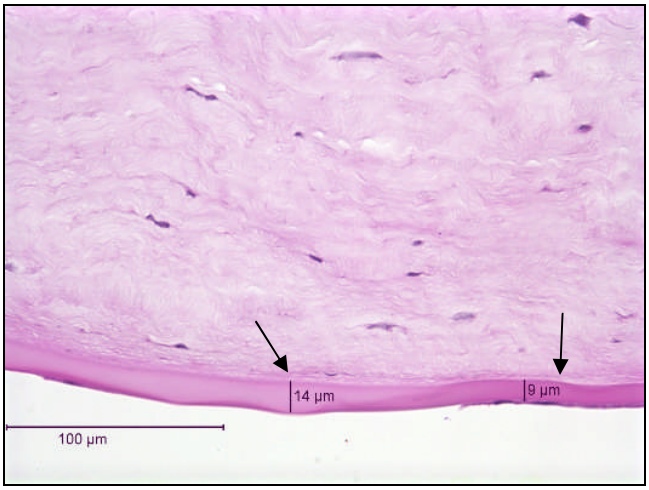

Bovine cornea treated with DIH_20 cut on a tangent such that Descemet's Membrane has two distinct sections.

Since there is no circulatory system in the isolated tissue, no leukocyte infiltration will be evident. The tissue sections must be of extremely good quality to evaluate stromal and endothelial elements properly because the early changes can be very subtle.

It is essential that all layers of the cornea be included in the section. Poorly trimmed blocks may produce sections where the full depth of the cornea is not present (e.g., the lower stroma and endothelium missing). It may be necessary to request recuts of such slides.

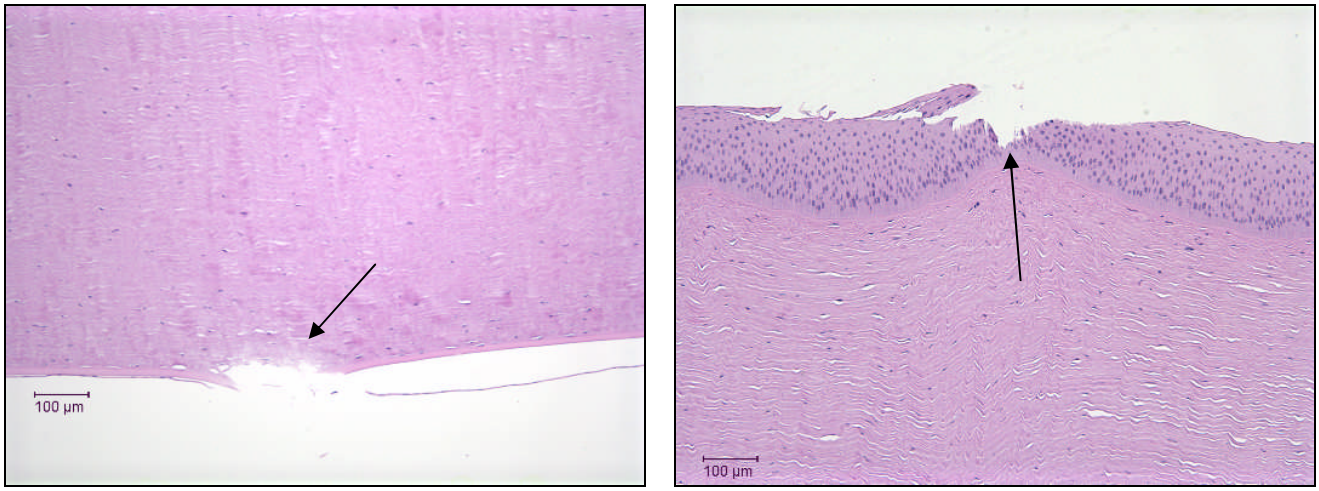

Bovine cornea treated with DIH_20 with lower stroma and endothelium missing (left figure), and epithelium missing (right figure).

Slides are usually stained with an automated slide stainer. The intensity of staining depends on several factors and may vary slightly across studies. Occasionally, a malfunction of the stainer will produce variations within the study. Decreased hematoxylin or eosin staining can markedly compromise interpretation and photography. Such slides should be returned for restaining or recutting. However, highly swollen stromal collagen will appear to be poorly stained but, in fact, there is a great deal of empty space between the fibers that is not stained at all.

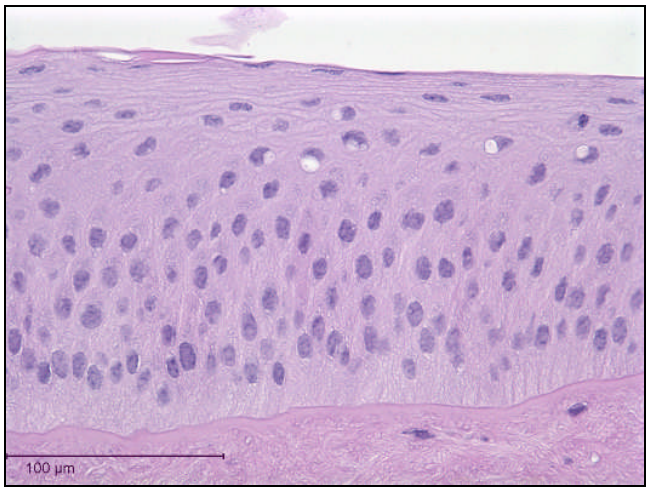

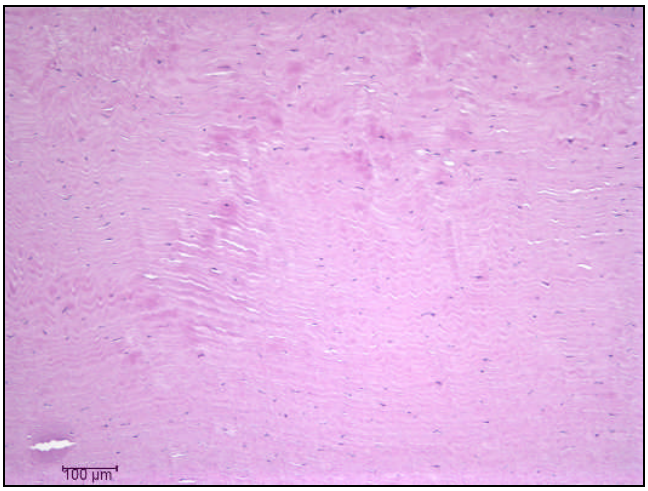

Bovine cornea treated with DIH_20 with hypoeosinophilic staining of the epithelium (left figure) and areas of hypereosinophilic staining of the stroma (right figure).

There are many other types of histological artifacts that are not presented here. Below is a selection of figures from DIH_20 treated bovine corneas which again show histological artifacts which result in difficulty interpreting the test article induced damage. These artifacts are, but not limited to, folding of the tissue, vibration of the blade, nick in the knife blade, and inadequate dehydration.

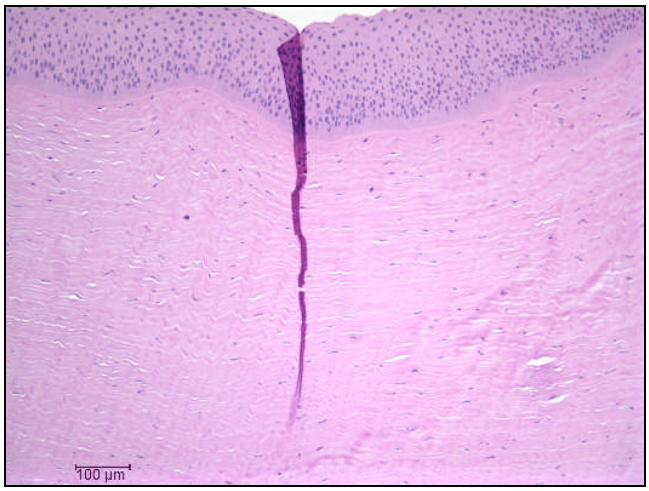

Folding of the tissue obscuring the epithelium and stroma

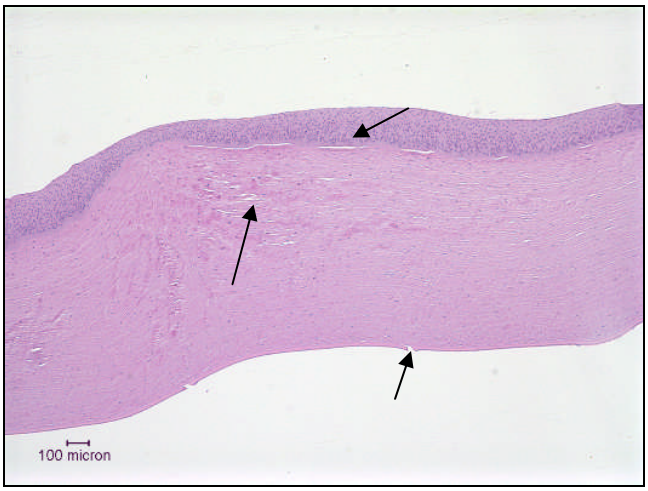

Microtomy artifacts (cuts in the endothelium, separation of the epithelium from Bowman's Layer)

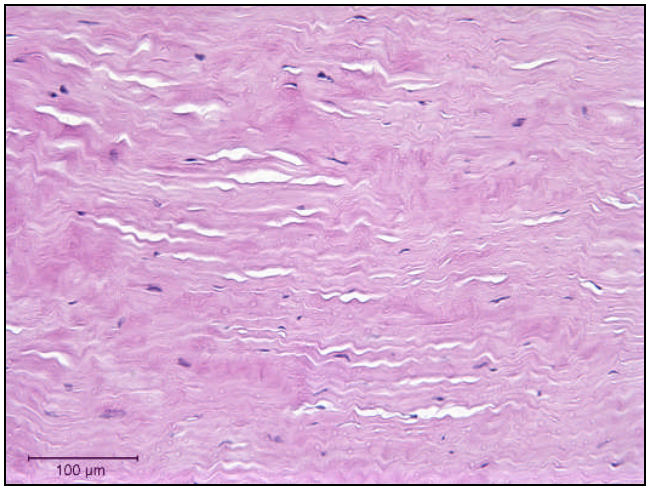

Vibration of the tissue specimen causing separation of the collagen in the stroma.

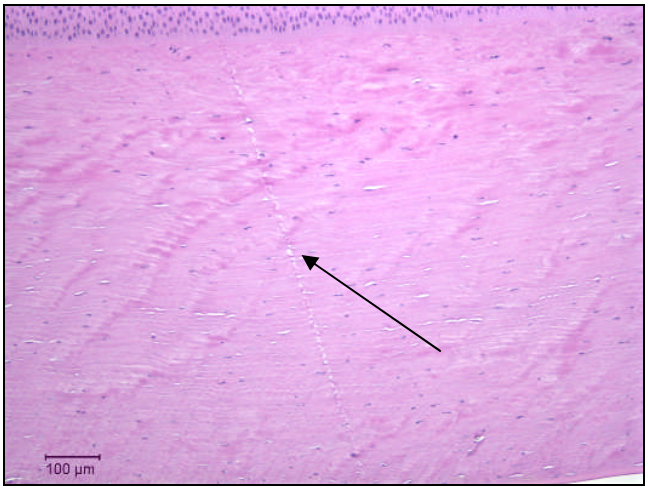

Nick in the knife black causing separation throughout the entire tissue.

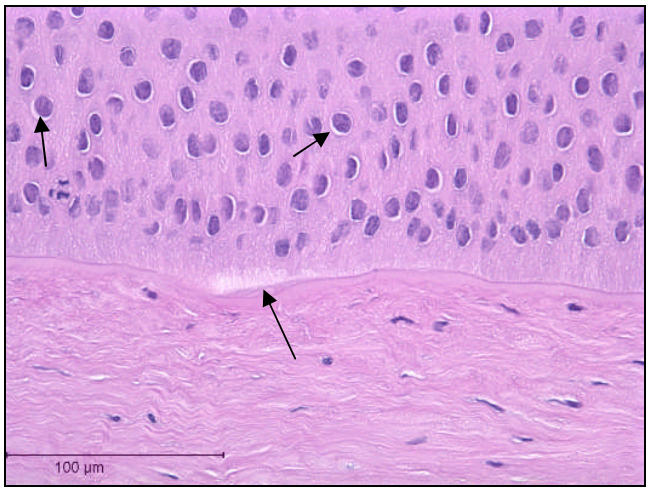

Microtomy artifact causing separation of the epithelium from Bowman's Layer and halo around the epithelium nuclei.

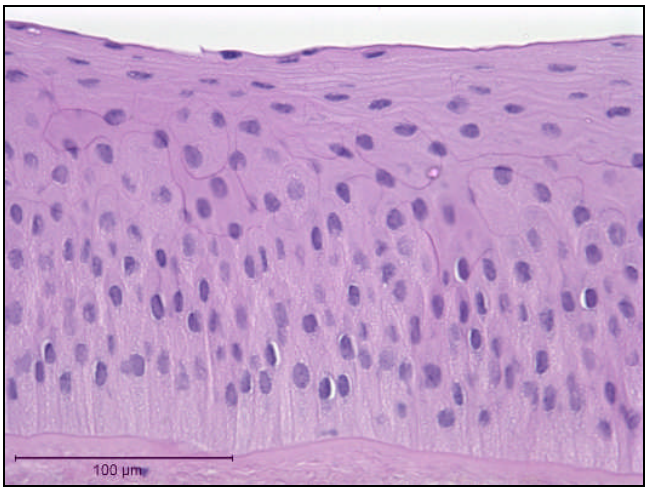

Inadequate dehydration of tissue causing artifacts appearing as bubbles.

4.3 Recording Observations

Observations of treated corneas are generally recorded electronically. The data include: the IIVS test article number, slide (cornea accession) numbers, sponsor's designation, test article concentration (relative to the test article as supplied), exposure time, post-exposure expression time, date of test article application, observations on each corneal tissue layer, and the related figure numbers (where appropriate). Once the observations are finalized, the table is included in the final report. The finalized observations are signed and dated by the responsible scientist. The original copy is placed into the study notebook.

The corneas will be photographed as part of the evaluation and the micrographs included in the final report to the client. Therefore, the flatness of the sections (on the slide) and the reproducibility of the staining from one study to the next (and especially within a study) become more important that if we were simply reading the slides.

4.4 Preparation of the Photomicrographs

Photomicrographs of the lesions are made to illustrate the degree of damage at the indicated depth observed in the treatment group. They are not intended to document the overall damage, as only a very small portion of the tissue can be photographed. Images are prepared using a Spot Insight Digital Camera and Spot 4.0.8 software (Diagnostic Instruments, Inc., Sterling Heights, MI). The color balance of the images is sometimes corrected to better represent the colors that would be seen through the microscope. Each photomicrograph is documented in a study-associated digital image log. A backup copy of the photomicrograph image files is made. Once finalized, the image log for the study is printed, signed and dated by the scientist responsible. The finalized copy is placed into the study notebook. The photomicrographs are "pasted" electronically into the final report.

4.1.1 Comparison of Human, Rabbit, and Bovine Corneas

Human cornea (Figure taken from Mamalis, Edelhauser et al. 2006)

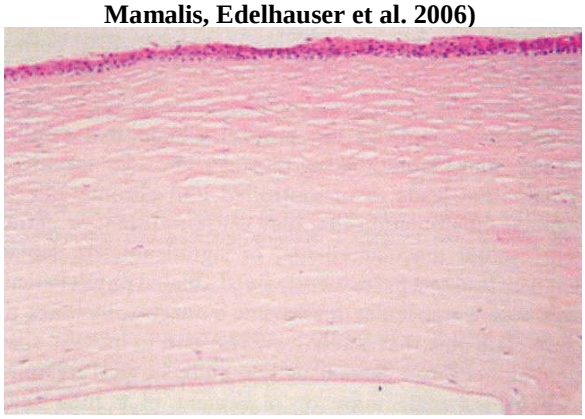

Bovine Cornea Dissected



Bovine Cornea Whole Globe

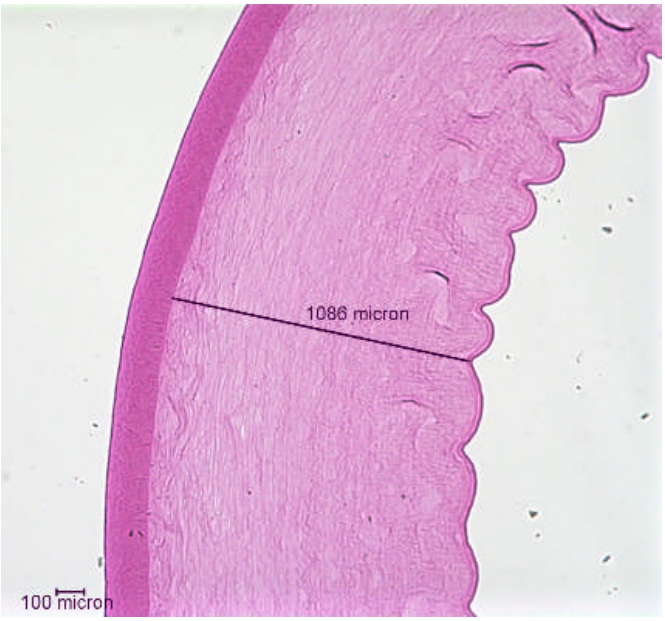

Rabbit Cornea Dissected

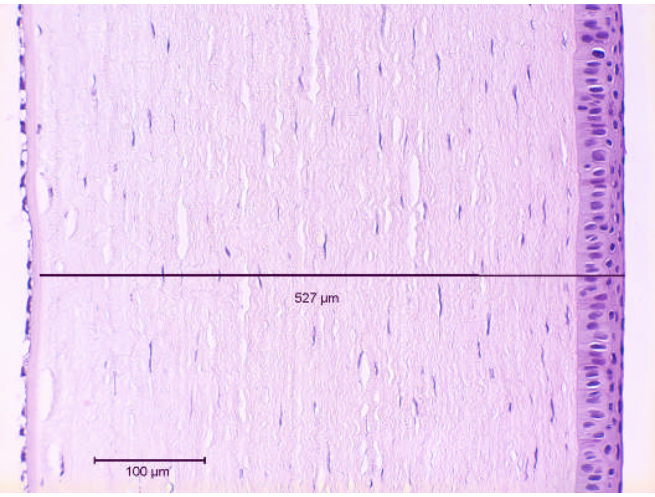

Rabbit Cornea Whole Globe

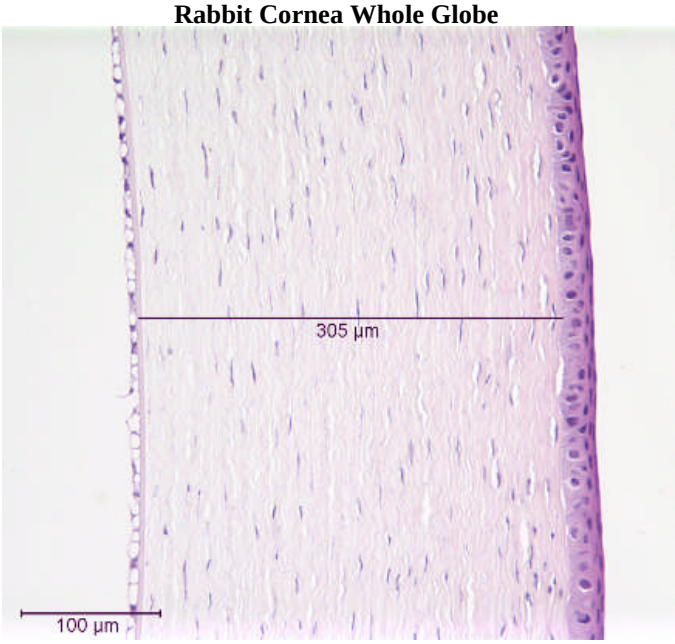

4.1.2 Evaluating the Negative Control-Treated Corneas

Negative control corneas are treated with sterile, deionized water or saline in parallel with the positive control and test article-treated corneas. The overall thickness of the bovine cornea is generally between 850-1000 µm.

Epithelium: The negative control-treated epithelium is composed of three layers. The basal cell layer is a well-formed, columnar-cell region directly attached to the basement membrane above Bowman's Layer. The basal cells are always tightly attached to each other. Rare mitotic figures are seen in the basal layer. Several layers of wing cells cover the columnar basal layer. In both of these layers, the cell nuclei typically show diffuse chromatin without clear nucleoli. The squamous layer is flattened with limited cytoplasm and highly condensed nuclei.

Stroma: The stromal elements begin with the Bowman's Layer and are composed of well-organized collagen matrix fibers with dispersed keratocytes. Keratocyte nuclei show a range of morphologies from moderate sized (smaller than the epithelial nuclei) with diffuse basophilic staining to narrow, elongated and condensed with dark basophilic staining. Cytoplasmic staining, when visible, is moderately basophilic. Rarely, cells with eosinophilic cytoplasmic staining may be observed. Collagen bundles are generally parallel and well ordered. The Descemet's Membrane is prominent and forms the bottom of the stroma. The overall thickness of the stroma is approximately one 20x field when a good cross section is obtained.

Endothelium: The endothelium is a single layer of flattened cells attached to the basal surface of the Descemet's Membrane. Nuclei are elongated and flattened. In a cross section, little cytoplasm is visible. Generally, the cells are firmly attached to the Descemet's Membrane but in some areas (or fields), they may be detached or lost through mechanical damage.

4.1.3 Evaluating the Corneal Lesions

The goal in scoring the corneal lesions is to record the nature, degree and depth of the lesion in each tissue layer. In most cases, the individual corneas in a treatment group will not be reported separately but rather they will be "averaged" to highlight the predominant lesions. The opacity and permeability values should be reviewed before scoring the slides. If there are wide variations among the corneas in either the indirect measures or histological changes, it may be necessary to report on some individual corneas within the treatment group.

Epithelium: Characteristic lesions observed in the epithelium are **cell loss**, **cell coagulation** (especially in the squamous epithelial layer), **nuclear vacuolization** (swelling), **nuclear condensation** (pyknosis or precipitation of nuclear proteins and/or DNA), **cytoplasmic vacuolization**, **cytoplasmic precipitation** (leaving only the cytoskeleton), and separation of the cells from the Bowman's layer. The degree of the lesion may be somewhat subjective. It

may be the fraction of the cells showing a lesion or the magnitude of the lesion within the cells or cell layer (e.g., degree of cytoplasmic vacuolization). The **depth of the lesion** relates to the number of cell layers impacted. Damage to or loss of the Bowman's Layer will be reported with the epithelium.

Stroma: The lesions of the stroma are reported in two parts; those of the **extracellular collagen matrix** and those of the **keratocytes**. The predominant lesions seen in the **extracellular collagen matrix** are **swelling** (loss of the normal ordered array of the fibers), and **stromal coagulation** or denaturation. Stromal swelling may be detected by the presence of vacuole-like "holes" in the organized collagen matrix. Their appearance suggests that liquid has entered the matrix, expanding space between the fibers. The **depth** (see below) **and degree of vacuolization** are reported. The **degree refers to the relative number and size of the holes in the matrix**. As the degree and/or depth of vacuolization increases, the overall thickness of the stroma would be expected to increase. **Stromal coagulation** appears frequently as areas with tightly bound collagen fibers with **hypereosinophilic** staining. The tightly bound collagen fibers may be interspersed between areas of stromal swelling or separation.

Since depth of injury (both extracellular and cellular) to the stroma is important in the analysis, a means to describe the depth of injury is necessary as part of this analysis. Determining the depth is not always a straight-forward process. Because of the topical application of the test article to the epithelium, one would expect that exposure to the stroma would progress from the area just under Bowman's Layer down through the stroma to Descemet's Membrane. There is no external inflammatory process in the isolated corneas, so one might also expect the progression of damage to follow the progression of exposure. That means that damage **to the stroma should first appear close to Bowman's Layer**. As the damage to the stroma increases, deeper layers might be involved. This implies that one would want to **express damage as progressing from the anterior (Bowman's Layer) to the posterior (Descemet's Membrane) and express it as a fraction of the total stromal depth involved.** However, collagen matrix vacuolization can increase stromal thickness. Thus, measurements of the depth of a stromal lesion can be complicated by the change in overall stromal thickness. Depth of stromal damage is reported as the <u>percentage of the normal corneal depth (cross section) involved,</u> starting from the anterior border (Bowman's Layer). However, to account for stromal swelling, this depth is actually estimated from the percentage of the stromal cross section that remained undamaged (starting at the posterior border). For example, a cornea reported to show collagen matrix vacuolization to 30% depth would mean that 70% of the cross section of that cornea (starting at Descemet's Layer) did not show vacuolization.

An exception to the anterior to posterior progression of stromal swelling is caused by the loss of the endothelial cell layer. **Since the endothelium is responsible for maintaining balanced hydration in the lower stroma, its**

loss (either through mechanical damage or test article toxicity) can lead to appreciable deep stromal swelling. It is important to differentiate between endothelial damage and swelling caused by the test article exposure and damage from other sources (e.g., mechanical). In the case of mechanical damage, the deep swelling can occur in the absence of swelling in the anterior stroma. **Test article-induced damage should progress through the cornea and be manifested in both the anterior and posterior stroma**. Sections or portions of sections where the endothelium is lost and posterior stromal swelling (collagen matrix vacuolization) is observed without similar anterior stromal swelling are likely the result of mechanical damage to the endothelium that occurred early in the assay (incubation). An effort should be made to score corneal sections that do not show such damage.

Lesions in the keratocytes are manifested in both the **cytoplasm and nucleus**. Rapid necrotic cell degeneration, as might follow exposure to a strong alkaline, organic solvent or surfactant, is quite apparent because the cellular components rapidly breakdown. Oxidative damage or DNA alkylation might produce more subtle damage (initially) but could also lead to cell death (delayed) and release of inflammatory mediators. **Nuclear changes (pyknosis or karyorrhexis**) are signs of this process. Progressive nuclear pyknosis or complete destruction are also signs of this process. **Cytoplasmic changes** include **vacuole formation or loss of basic elements** (mRNA for example) that are also indicative of the beginning of the degenerative process. The cell cytoplasm normally stains with both basophilic (hematoxylin) and acidophilic (eosin) stains. When the basic elements are lost, eosinophilic staining predominates. This change is termed **keratocyte eosinophilia**.

Endothelium: Lesions in this layer include **cell loss and cytoplasmic degeneration (vacuolization**). Since this layer is only one cell thick, mechanical damage has the potential to confound the evaluation. Where there is endothelial cell loss, it is important to evaluate surrounding fields for the presence of normal endothelium. Since the whole corneal surface is treated, a lack of a uniform changes to most of the endothelium would suggest mechanical damage to isolated patches rather than test article-induced damage. When mechanical damage occurs late in the assay or after fixation (e.g., during processing), little or no deep stromal swelling is expected.

4.2. A short compendium of micrographs to illustrate negative control-treated (normal) and select lesions in bovine corneal tissue

The following series of photomicrographs are intended to illustrate normal bovine corneal morphology and provide examples of the types of lesions that might be observed in the epithelium, stroma, and endothelium. It is by no means a complete listing of all lesions, but is intended to illustrate the types of changes mentioned in the discussion of corneal lesions. In some figures, the chemical and exposure are provided. When photomicrographs have been taken from unpublished client studies, test material information is omitted.

4.2.1 Negative Control Corneas

Figure 1 Negative control cornea (sterile, deionized water, 10-minute exposure, 2 hour post exposure) – Full thickness (4X)

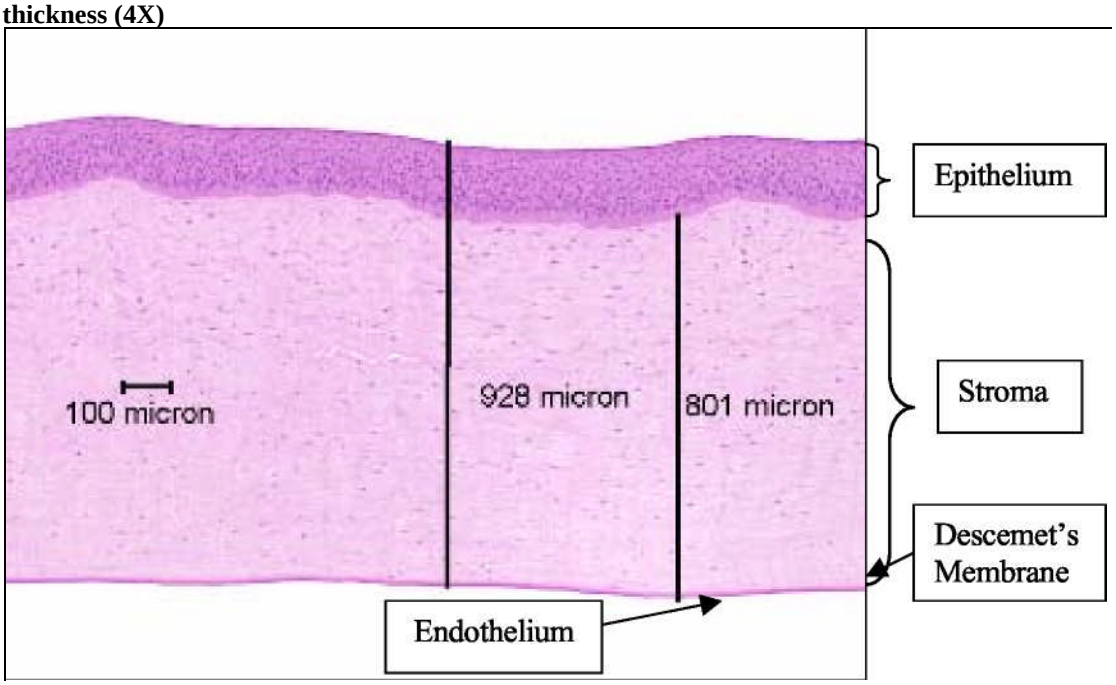

Figure 2 Negative control cornea (sterile, deionized water, 10-minute exposure, 2 hour post-exposure) – Epithelium (20X)

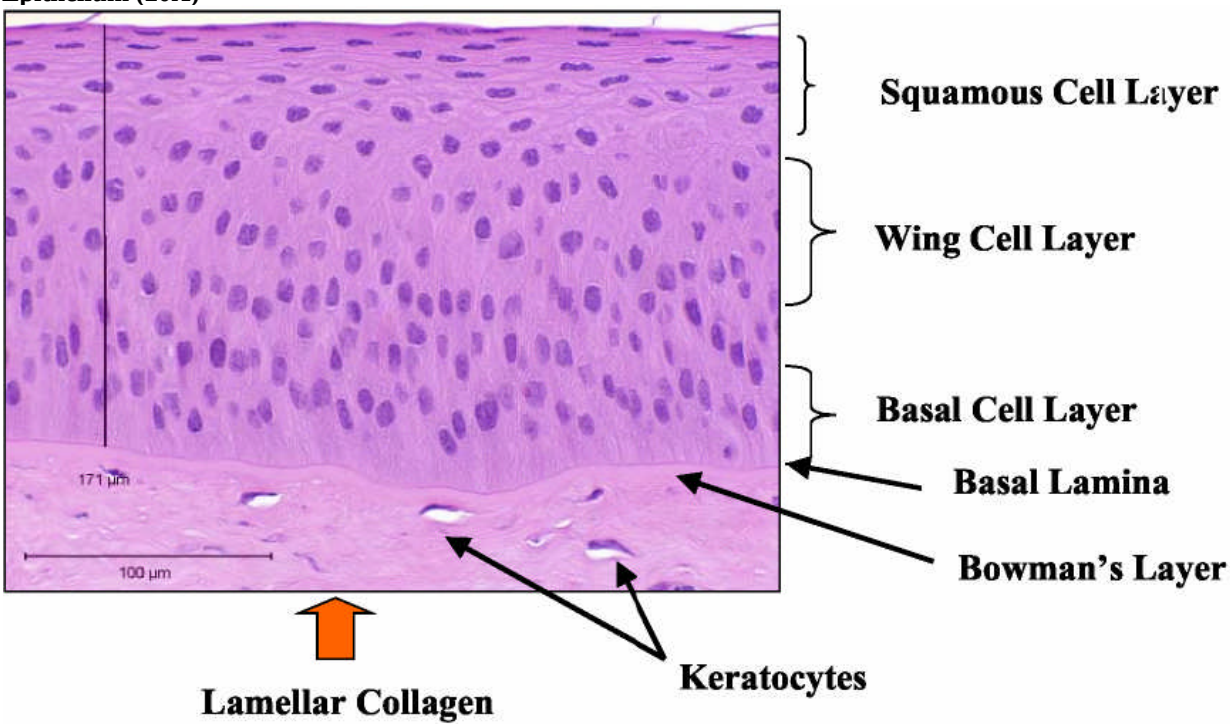

Figure 3 Negative control cornea (sterile, deionized water, 10-minute exposure, 2 hour post-exposure) - Upper stroma showing normal collagen matrix organization and keratocyte morphology (40X)

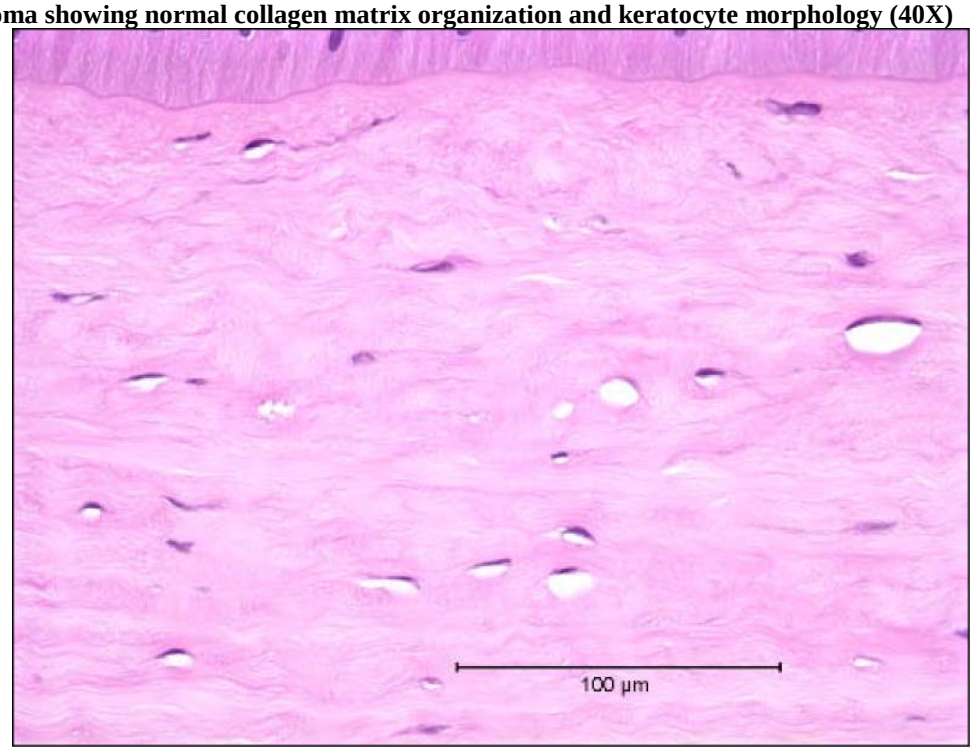

Figure 4 Negative control cornea (sterile, deionized water, 10-minute exposure, 2-hour post-exposure) - Deep stroma and endothelium (40X)

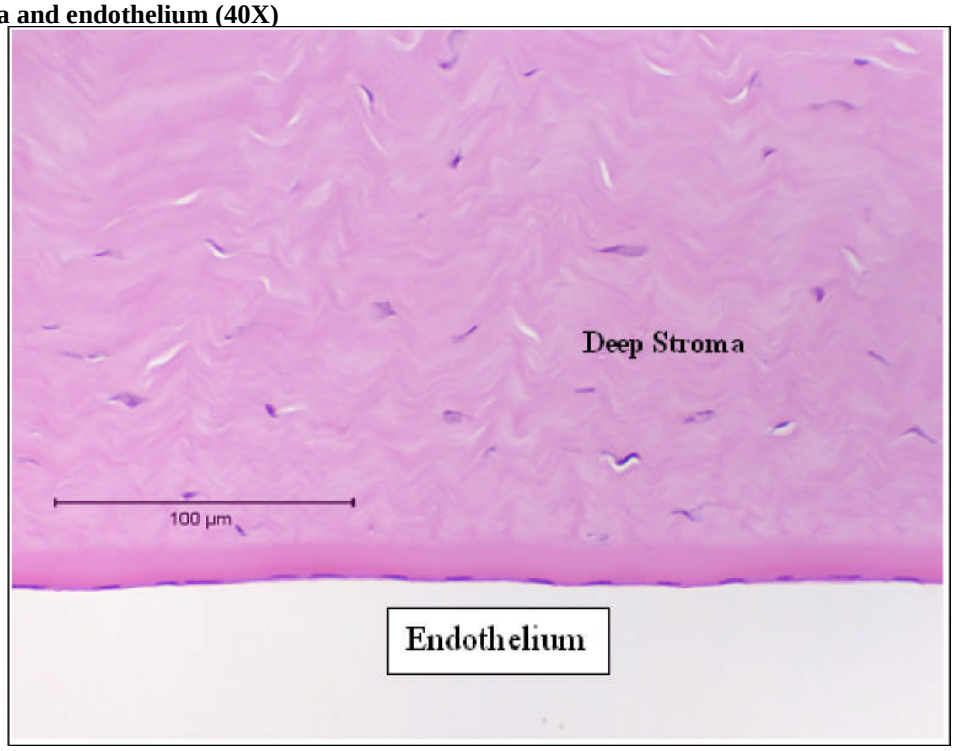

4.2.2 Epithelial Damage

Figure 5 Sodium Lauryl Sulfate (1% SLS (1/8/01), 30-minute exposure) - Epithelial cell loss induced by surfactant exposure (40X)

Opacity 3.2	Permeability 0.772	*In Vitro* Score 14.7

Figure 6 Sodium Lauryl Sulfate (5% SLS (1/8/01), 30-minute exposure) – Epithelial cell loss induced by surfactant exposure (40X)

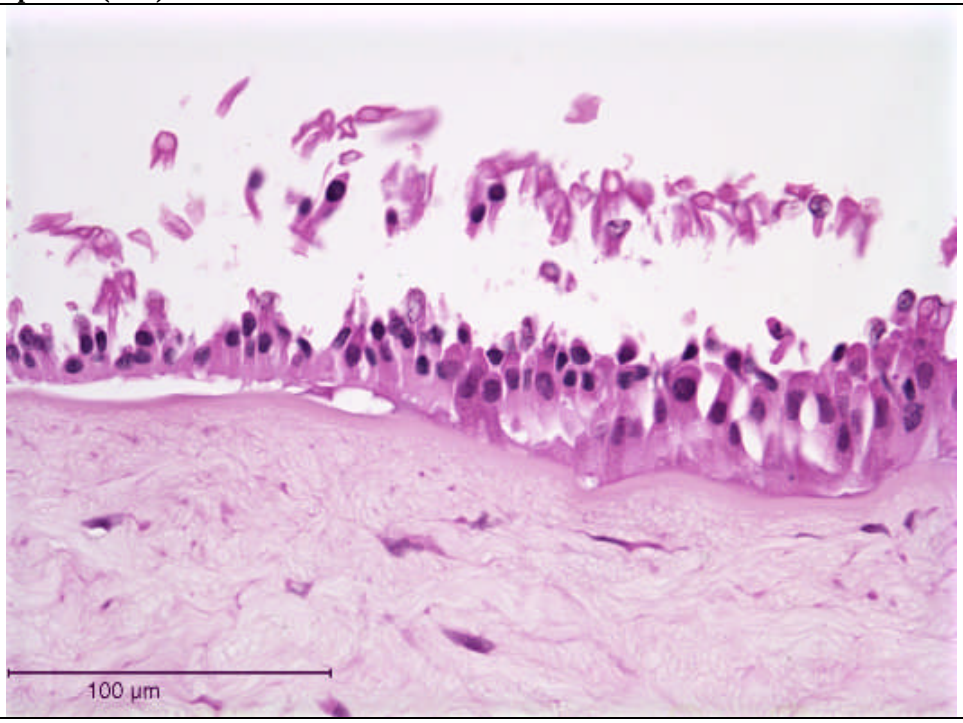

Opacity 37.7	Permeability 2.538	*In Vitro* Score 45.7

Figure 7 Ethanol (neat ETOH (2/6/07), 10-minute exposure, 2-hr post-exposure) – Squamous layer coagulation and cytoplasmic and nuclear vacuolization in the wing and basal layers (20X)

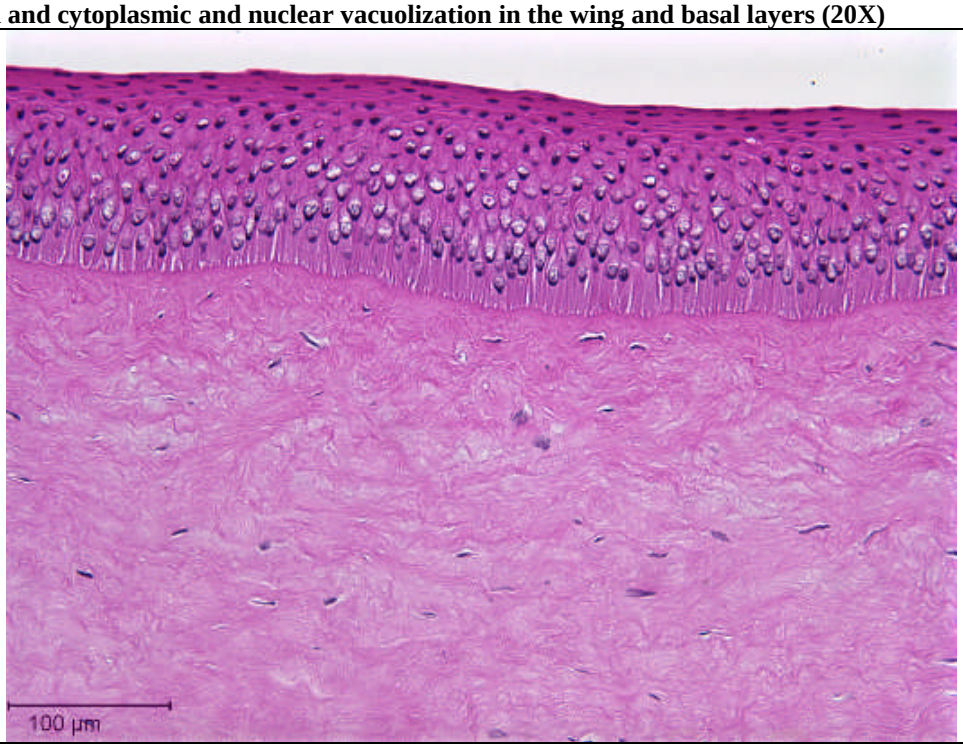

Opacity 24.8	Permeability 1.476	*In Vitro* Score 47.0

Figure 8 Acid formulation "A" (neat (4/15/04, 6/3/04), 3-minute exposure, 2-hr post-exposure) Moderate coagulation, abnormal chromatin condensation and cytoplasmic vacuolization in the squamous and upper wing cell layers (40X)

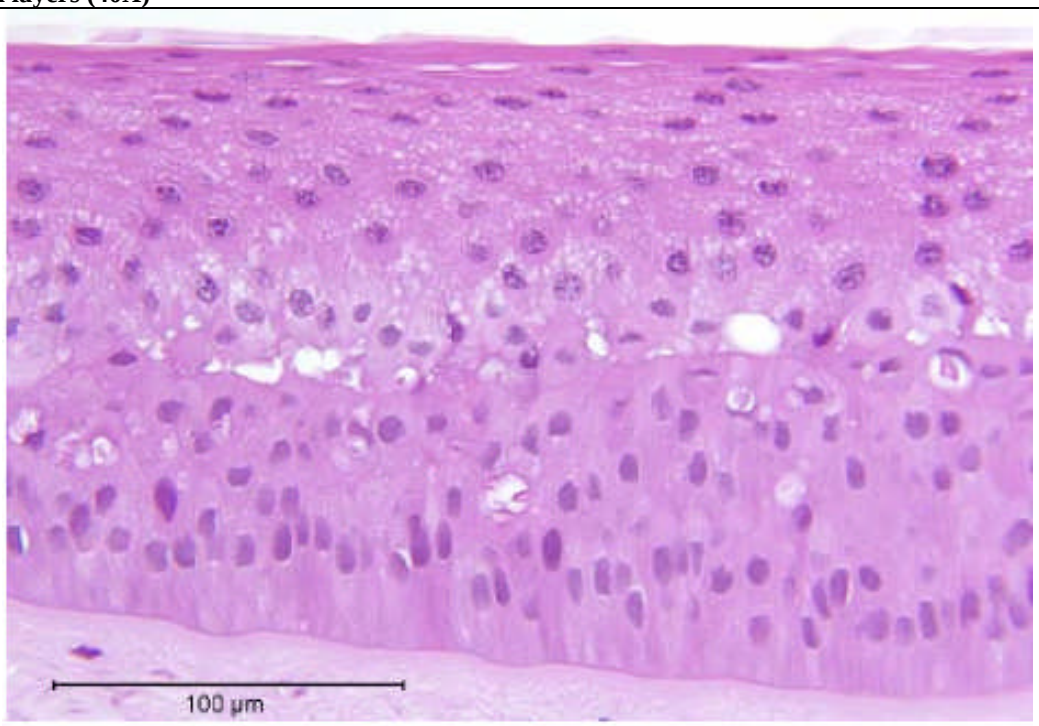

Opacity 53.3	Permeability 0.533	*In Vitro* Score 61.3

Figure 9 Acid formulation "B" (neat (4/15/04, 6/3/04), 3-minute exposure, 2-hr post-exposure) Marked squamous cell coagulation, abnormal chromatin condensation and breakdown of basal cell adhesion to the basal lamina (40X)

Opacity 34.0	Permeability 0.911	*In Vitro* Score 47.7

Figure 10 Acid formulation "B" (neat (4/15/04, 6/3/07), 10-minute exposure, 2-hr post-exposure) Severe squamous cell coagulation, abnormal chromatin condensation (precipitation) and marked cytoplasmic eosinophilia (40X)

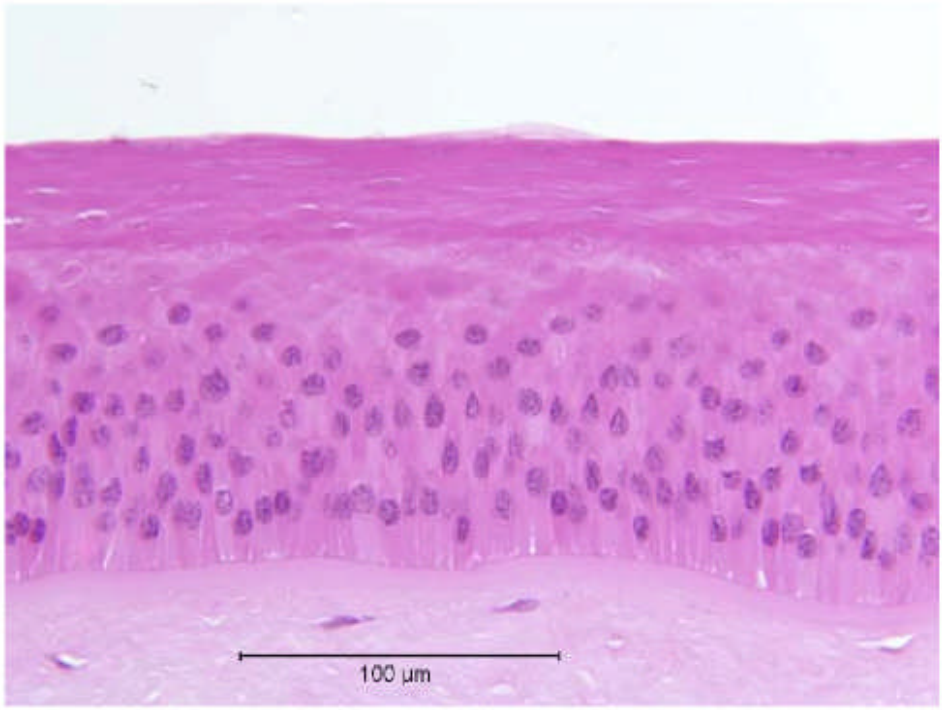

Opacity 46.7	Permeability 1.682	*In Vitro* Score 71.9

Figure 11 (neat (7/28/03, 1/16/04)) 10-minute exposure, 2-hr post-exposure) Hypo-chromic staining in the upper epithelium and marked nuclear pyknosis and upper hyper-eosinophilia in the deep epithelium (20X)

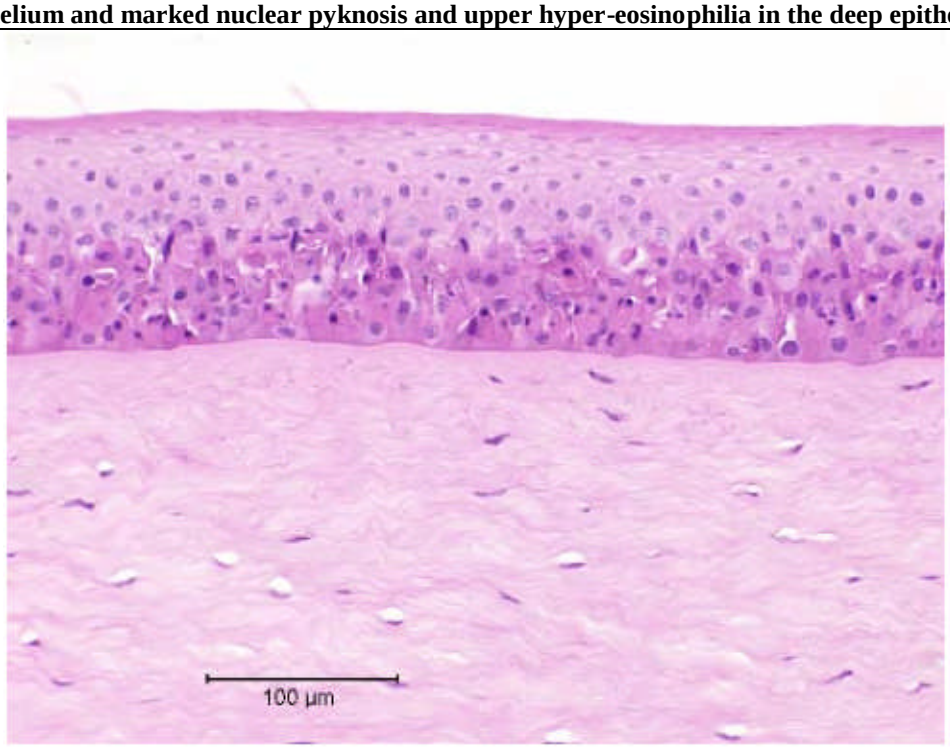

Opacity 15.2	Permeability 0.512	*In Vitro* Score 22.9

Figure 12 (neat (5/10/04, 9/1/04)) Organic solvent-induced loss of cellular structure and cytoplasmic contents in the epithelium

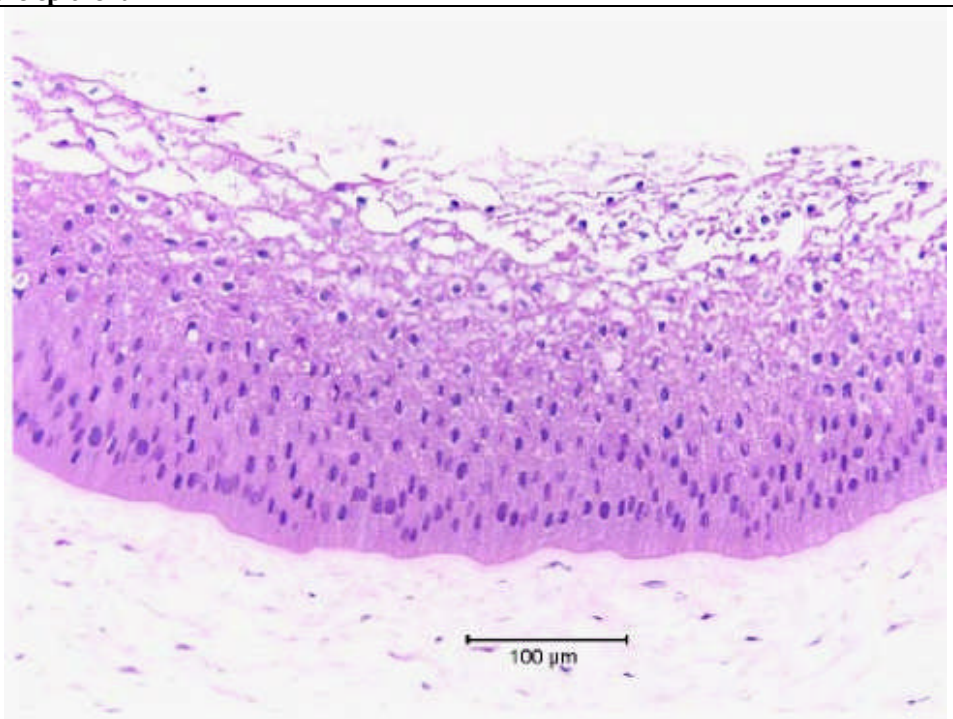

Opacity 42.2	Permeability 0.556	*In Vitro* Score 50.5

Figure 13 (neat (10/2/03, 1/4/04), 10-minute exposure, 4-hr post-exposure) Overall destruction of the epithelium and separation from the basal lamina. Note the eosinophilic precipitate between the Bowman's Layer and basal cells (20X)

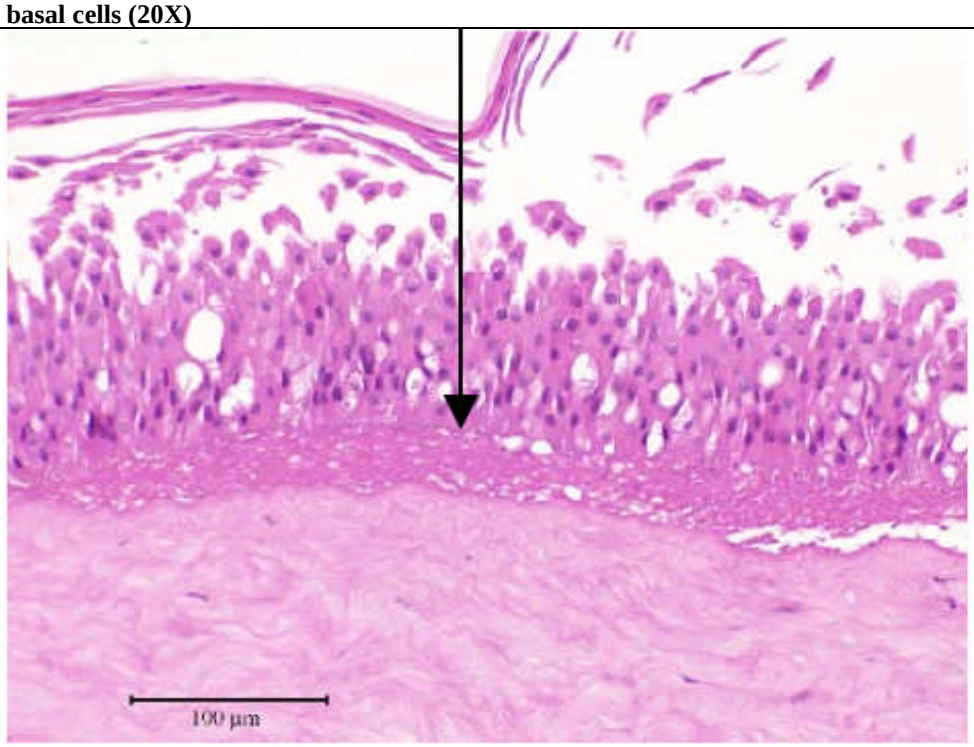

Opacity 18.3	Permeability 0.453	*In Vitro* Score 25.1

Figure 14 Damage to the epithelium and upper stroma resulting in a complete loss of viability and reduced staining.

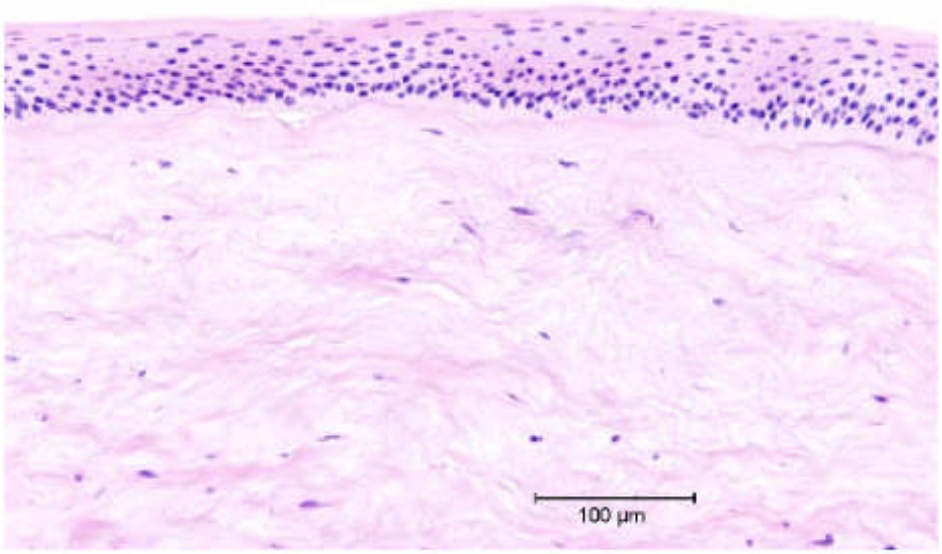

Opacity	Permeability	*In Vitro* Score

Figure 15 Bleach Mixture (neat 9/27/06, 1/4/07), 10-minute exposure, 2-hour post exposure) Epithelium showing complete loss of nuclear and cytoplasmic staining in the squamous cell layer and upper wing layer.

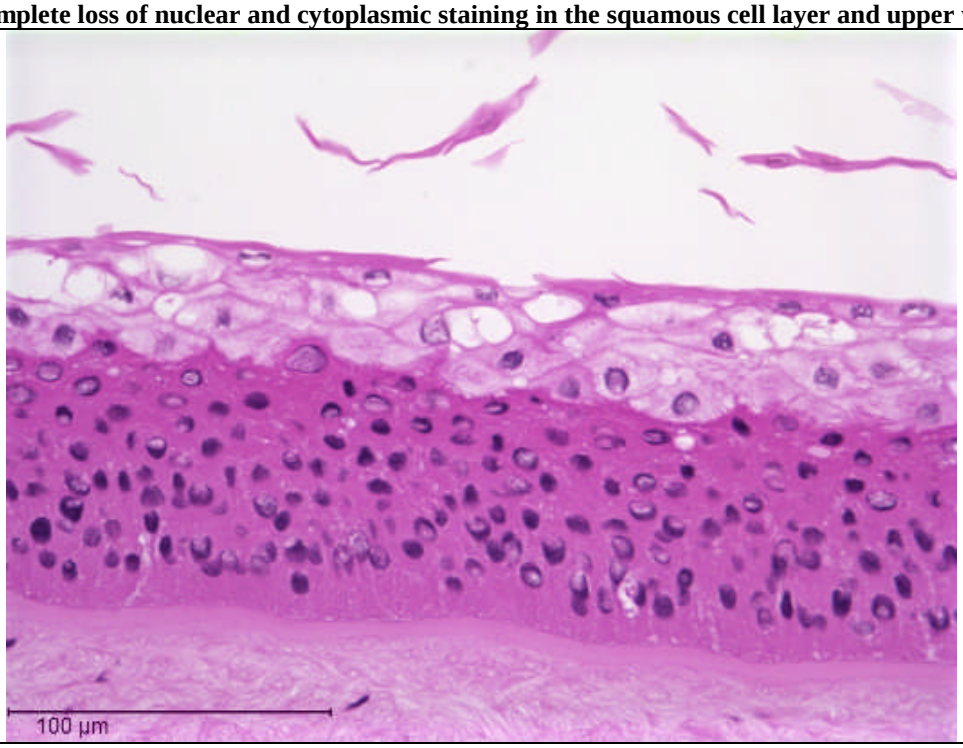

Opacity 14.7	Permeability 0.082	*In Vitro* Score 15.9

Figure 16 Bleaching Agent (neat (5/23/07, 6/27/07), 3-minute exposure, 2-hr post-exposure) Epithelium showing microvacuolation of cellular structure and cytoplasm

Opacity 89.2	Permeability 2.145	*In Vitro* Score 121.3

4.2.3 Stromal Lesions

Figure 17 Sodium Lauryl Sulfate (1.5% SLS (3/24/05), 10-minute exposure, 2-hr post-exposure) Example of slight collagen matrix vacuolization directly below Bowman's Layer

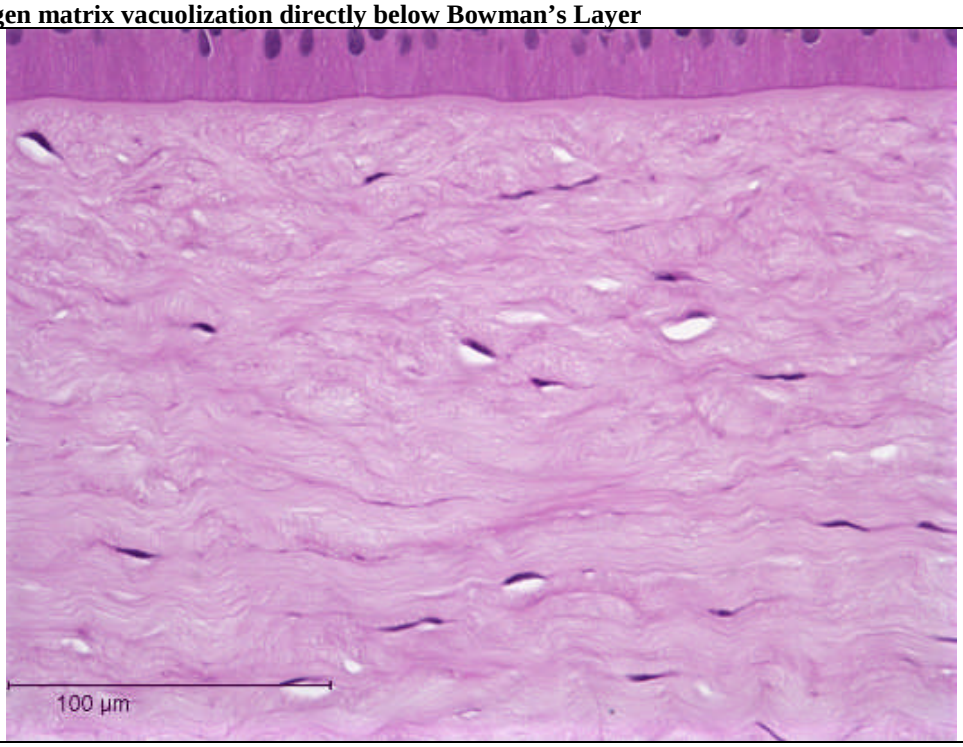

Opacity 2.2	Permeability 0.379	*In Vitro* Score 7.8

Figure 18 Sodium Lauryl Sulfate (1% SLS (1/8/01), 30-minute exposure) Example of moderate collagen matrix vacuolization in the upper stroma

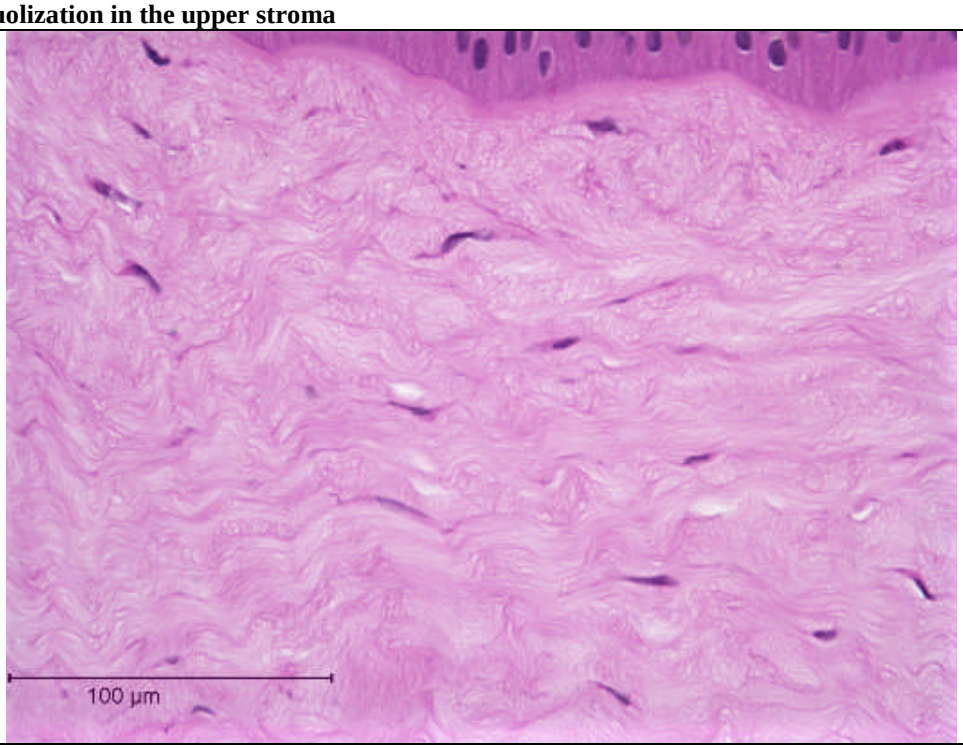

Opacity 3.2	Permeability 0.772	*In Vitro* Score 14.7

Figure 19 Sodium Lauryl Sulfate (5% SLS (1/8/07), 30-minute exposure) Example of moderate to marked collagen matrix disorganization and vacuolization in the upper stroma. Note also the keratocyte nuclear changes.

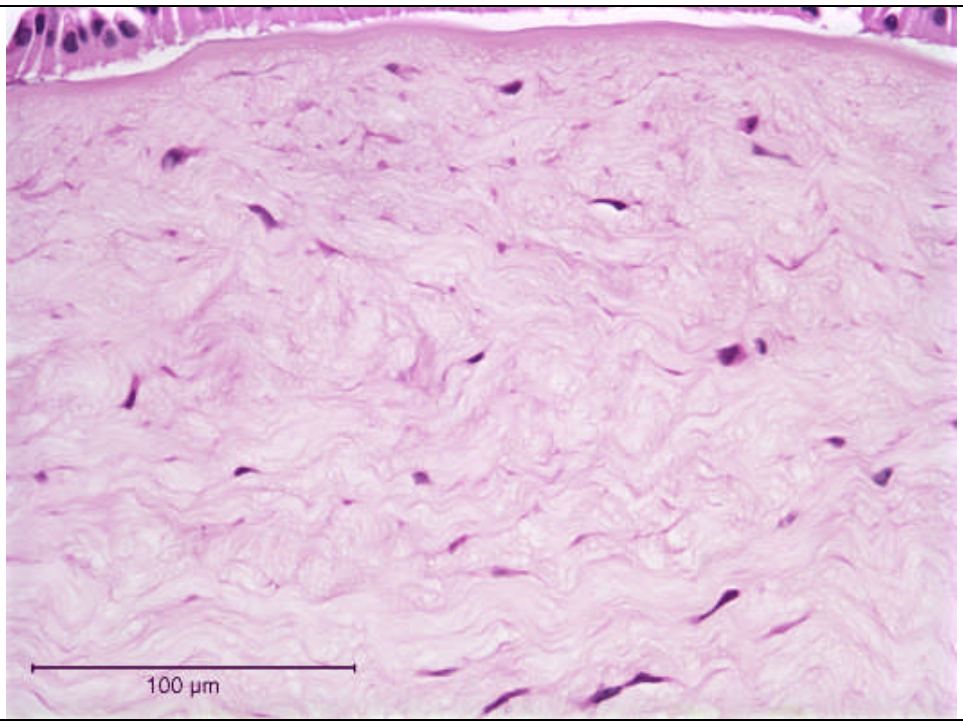

Opacity 7.7	Permeability 2.538	*In Vitro* Score 45.7

Figure 20 Sodium Lauryl Sulfate (10% SLS (1/8/01), 30-minute exposure) Severe collagen matrix vacuolization following destruction of the epithelium. Note also the destruction of the upper keratocytes

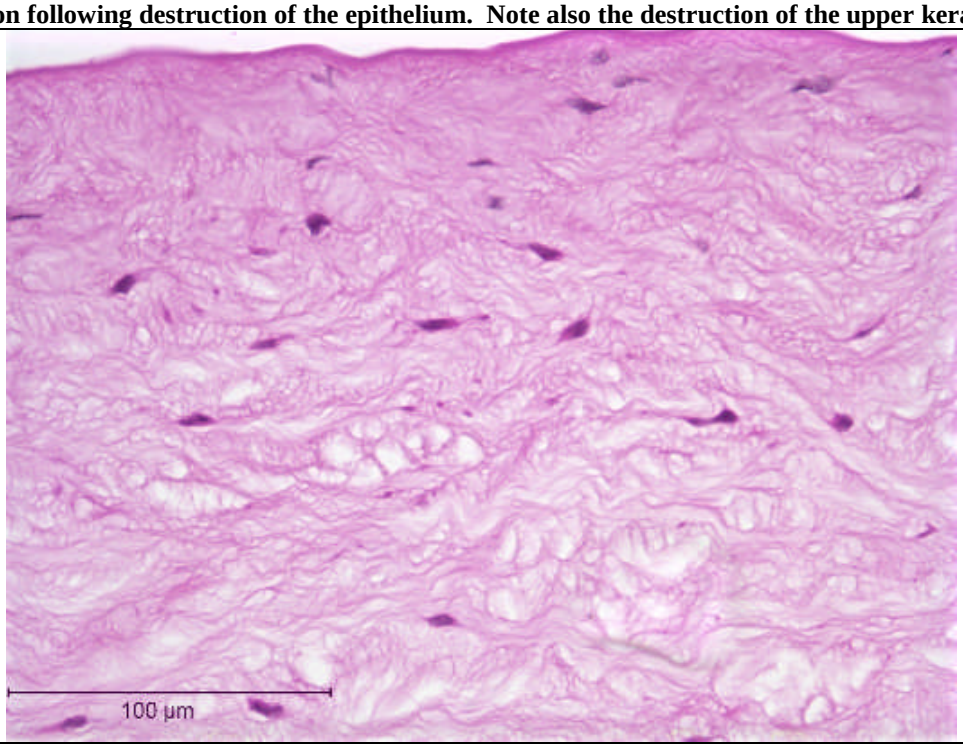

Opacity 3.7	Permeability 2.665	*In Vitro* Score 43.6

4.2.4 Endothelial Cell Lesions

Figure 21 Quinacrine (20% Quinacrine in MEM (11/24/98), 4-hour exposure) Endothelial cell vacuolation (severe)

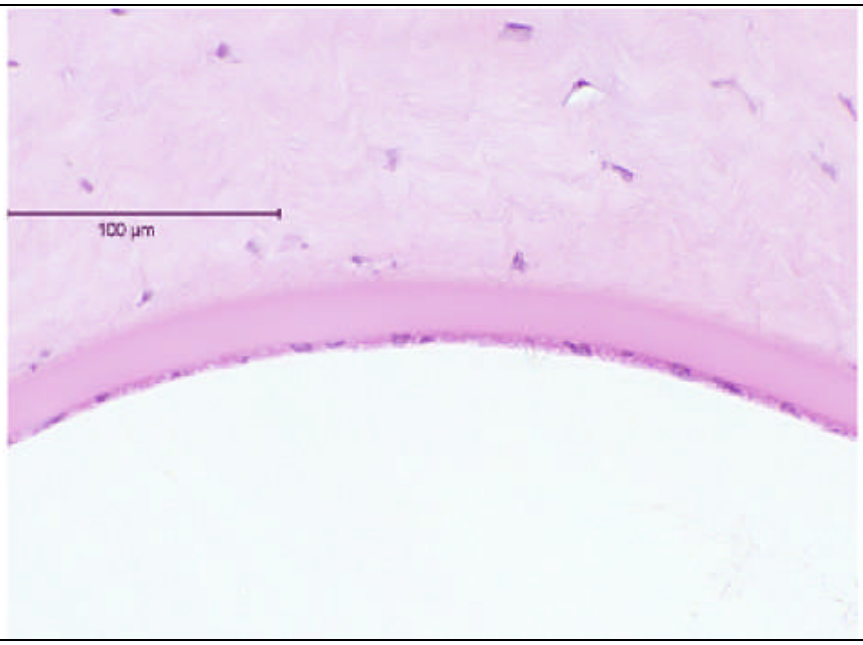

Opacity 10.5	Permeability -0.040	*In Vitro* Score 9.9

Figure 22 Bleach Mixture (neat 9/27/06, 1/4/07), 10-minute exposure, 2-hour post exposure) Damage to the endothelial cell layer, cytoplasmic, and deep stromal collagen matrix vacuolization (severe).

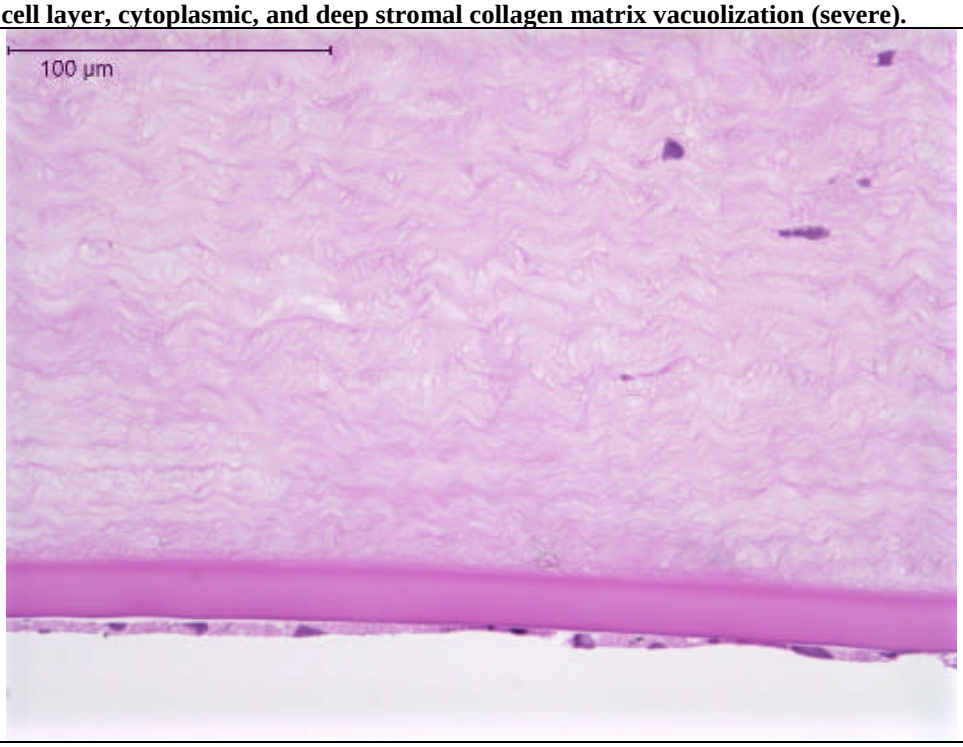

Opacity 14.7	Permeability 0.082	*In Vitro* Score 15.9

Figure 23 (neat (1/17/07, 2/15/07), 10-minute exposure, 2-hr post-exposure) Loss of endothelium with minimal lower stroma collagen matrix vacuolation and disorganization.

Opacity -0.3	Permeability -0.003	*In Vitro* Score -0.3

Figure 24 Ethanol (neat ETOH (10/27/05, 4/27/06), 10-minute exposure, 2-hr post-exposure) Severe damage to the epithelium and swelling of the upper stroma. The endothelium was intact and little swelling was observed in the deep stroma.

Opacity 33.0	Permeability 0.978	*In Vitro* Score 47.7

Figure 25 (50%(w/v) (3/27/02, 6/2/02), 30-minute exposure, 24-hour post-exposure) Example of massive stromal swelling resulting from the loss of both the epithelium and endothelium (severe).

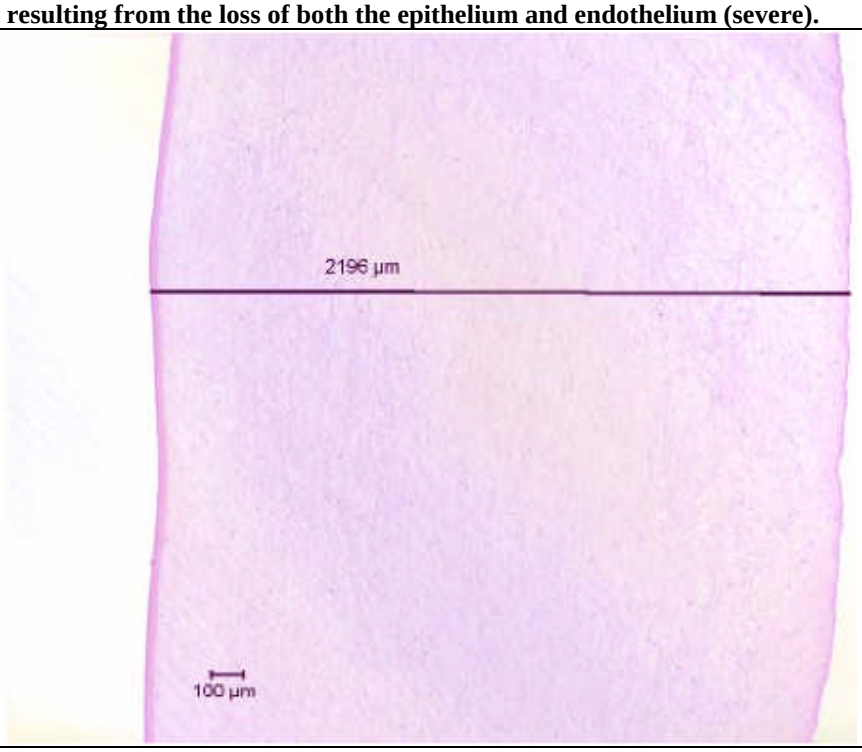

Opacity 27.7	Permeability 1.392	*In Vitro* Score 48.5

5. References

Araki, K., Y. Ohahsi, S. Knoshita, K. Hayahsi, Y. Kuwayama and Y. Tano (1994). "Epithelial Wound Healing in the Denervated Cornea." Current Eye Research **13**: 203-211.

Baldwin, H. A., T. O. McDonald and C. H. Beasley (1973). "Slit examination of experimental animals eyes. II Grading scales and photographic evaluation of induced pathological conditions." J Society of Cosmetic Chemistry **24**: 181-195.

Butler, J. M. and B. R. Hammond (1980). "The Effects of Sensory Denervation on the Response of the Rabbit Eye to prostaglandin E1, bradykinin and substance P." British Journal of Pharmacology **69**: 495-502.

Chan, P. K. and A. W. Hayes (1994). "Acute Toxicity and Eye Irritancy." In Principles and Methods of Toxicology, 3rd Edition (ed Hayes A.W.): 579-647.

Cuellar, N., J. Merrill, M. Clear, G. Mun and J. W. Harbell (2002). "The Application of Benchmarks for the Evaluation of the Potential Ocular Irritancy of Aerosol Fragrances." The Toxicologist **66**(1): 243-244.

Curren, D. R., M. G. Evans, H. Raabe, R. R. Ruppalt and J. Harbell (2000). "Correlation of Histopathology, Opacity, and Permeability of Bovine corneas Exposed *In Vitro* to Known Ocular Irritants." Veterinary Pathology **37**(5): 557.

Dearman, R. J., M. Cumberbatch and I. Kimber (2003). "Cutaneous Cytokine Expression: Induction by Chemical Allergen and Paracrine Regulation." Journal of Toxicology-Cutaneous and Ocular Toxicology **22**: 69-86.

Dua, H. S., J. A. P. Gomes and A. Singh (1994). "Corneal Epithelium Wound Healing." British Journal of Ophthalmology **78**: 401-408.

Eurell, T. E., J. M. Sinn, P. A. Gerding and C. L. Alden (1991). "In Vitro Evaluation of Ocular Irritants Using Corneal Protein Profiles." Toxicology and Applied Pharmacology **108**: 374-378.

Farquhar, M. G. and G. E. Palade (1963). "Junctional complexes in Various Epithelia. ." J Cell Biology **17**: 375-412.

Gautheron, P., M. Dukic, D. Alix and J. F. Sina (1992). "Bovine Corneal Opacity and Permeability Test: An *In Vitro* Assay of Ocular Irritancy." Fundam Appl Toxicol **18**(3): 442-9.

Hackett, R. B. and T. O. McDonald (1994). "Mechanisms of Ocular Response to Irritants." Dermatotoxicology, 5th Editions, (ed Marzulli F.N, Maibach H.I.): 299-306.

Hogan, M. J. and L. E. Zimmerman (1962). "Ophthalmic Pathology: An Atlas and Textbook, 2nd edition." Philadelphia: W.B. Saunders.

Hubert, F. (1992). "The Eye (Rabbit/Human): Parameters to be Measured in the Field of Ocular Irritation." ATLA **20**: 476-479.

Jacobs, G. A. and M. A. Martens (1990). "Quantification of Eye Irritation Based Upon In Vitro Changes of Corneal Thickness." ATLA **17**: 255-262.

Katahira, J. H., H. Sugiyama, N. Inoue, Y. Horiguchi, M. Matsuda and N. Sugimoto (1997). "Clostridium Perfringens Enterotoxin Utilizes Two Structurally Related Membrane Proteins as Functional Receptors in Vivo." J Biological Chemistry **272**: 26652-26658.

Klyce, S. D. and R. W. Beuerman (1988). "Structure and Function of the Cornea." The Cornea: 3-23.

Mamalis, N., H. F. Edelhauser, D. G. Dawson, J. Chew, R. M. LeBoyer and L. Werner (2006). "Toxic Anterior Segment Syndrome." J Cataract Refract Surg **32**(2): 324-332.

Maurer, J. K., A. Molai, R. D. Parker, L. Li, G. J. Carr, W. M. Petroll, et al. (2001). "Pathology

of Ocular Irritation with Bleaching Agents in the Rabbit Low-volume Eye Test." Toxicol Pathol **29**(3): 308-319.

Maurer, J. K. and R. D. Parker (1996). "Light Microscope Comparison of Surfactant Induced Eye Irritation in Rabbits and Rats at Three Hours and Recovery/day 35." Toxicologic Pathology **24**: 403-411.

Maurer, J. K., R. D. Parker and J. V. Jester (2002). "Extent of Initial Corneal Injury as the Mechanistic Basis for Ocular Irritation: Key Findings and Recommendations for the Development of Alternative Assays." Regul Toxicol Pharmacol **36**(1): 106-117.

Maurer, J. L. and R. D. Parker (1996). "Light Microscope Comparison of Surfactant-induced Eye Irritation in Rabbits and Rats at Three Hours and Recovery/day 35." Toxicologic Pathology **6**: 464-477.

Sina, J. F., D. M. Galer, R. G. Sussman, P. D. Gautheron, E. V. Sargent, B. Leong, et al. (1995). "A Collaborative Evaluation of Seven Alternatives to the Draize Eye Irritation Test Using Pharmaceutical Intermediates." Fundamental and Applied Toxicology **26**: 20-31.

Swanson, J. E., B. T. White, B. P. Gran, J. Merrill and J. Harbell (2003). "Evaluating Oxidizing/reactive Cleaning Products in the Bovine Corneal Opacity and Permeability (BCOP) Assay." The Toxicologist **72**: 220-221.

Van Meer, G., W. van Hof and I. and Genderen (1992). "Tight Junctions and Polarity of Lipids " Tight Junctions (ed Cereijido M.): 187-201.

Wilhelmus, K. R. (2001). "The Draize Eye Test." Surveys in Ophthalmology **45**: 493-515.