SOLVENT MATERIALS

06AG29, neat, 3-minute exposure, 120-minute post-exposure (8/15/06) – Full thickness (magnification 4X). Upper right - Epithelium with loss of the squamous layer (magnification 40X). Lower right - Superficial stroma with expansion of the collagen matrix (A) and keratocytes with eosinophilic cytoplasm (B) (magnification 40X).

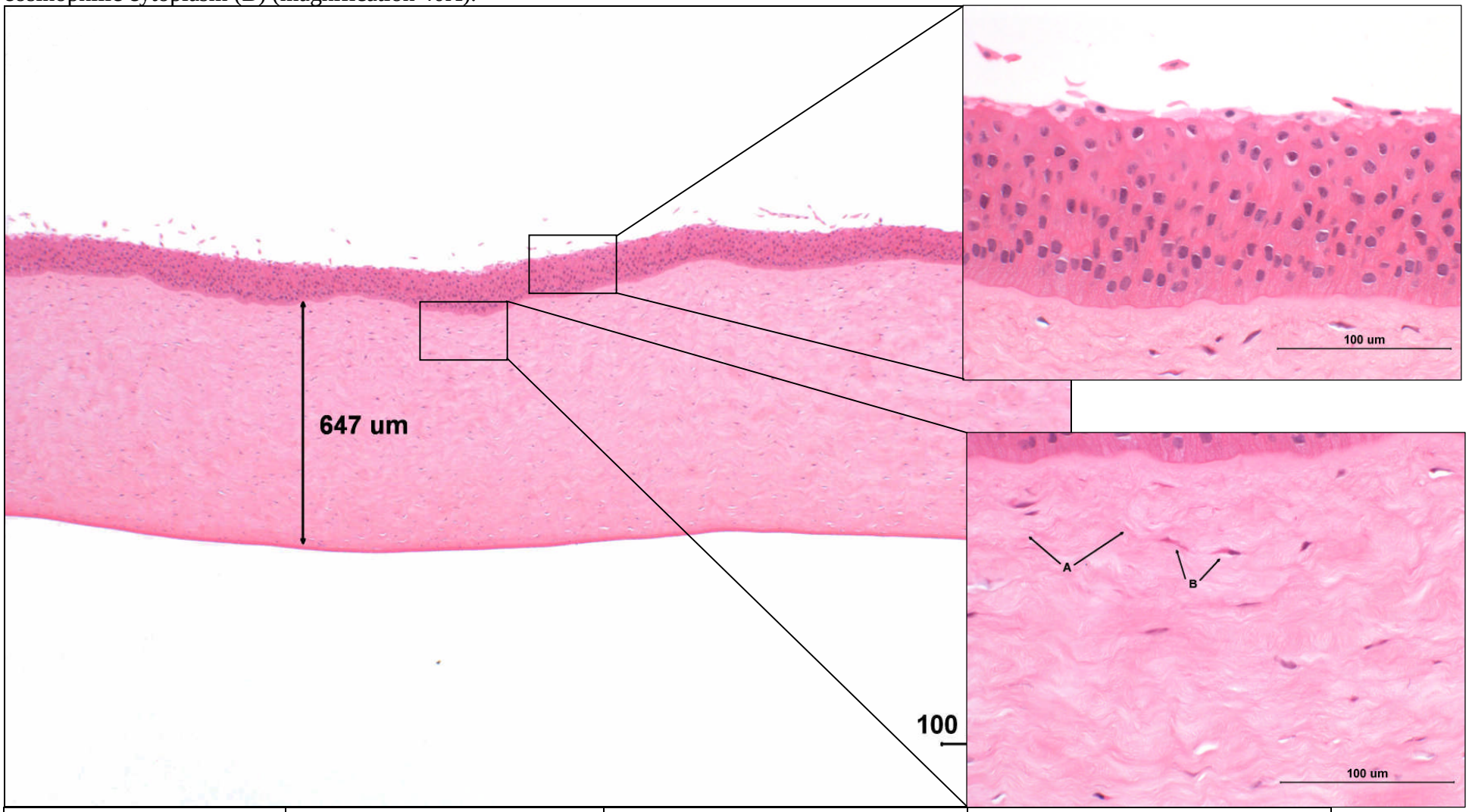

Opacity = 4.3	Permeability = 0.565	*In Vitro* Score = 12.8	pH = 3.5

06AG29, neat, 10-minute exposure, 120-minute post-exposure (8/15/06) –Full thickness (magnification 4X). Upper right – Epithelium with full thickness necrosis and sloughing (magnification 40X). Lower right – Upper stroma with expansion of the collagen matrix (A), nuclear pyknosis (B), vacuolated keratocyte nuclei (C), and eosinophilic cytoplasm (D) (magnification 40X).

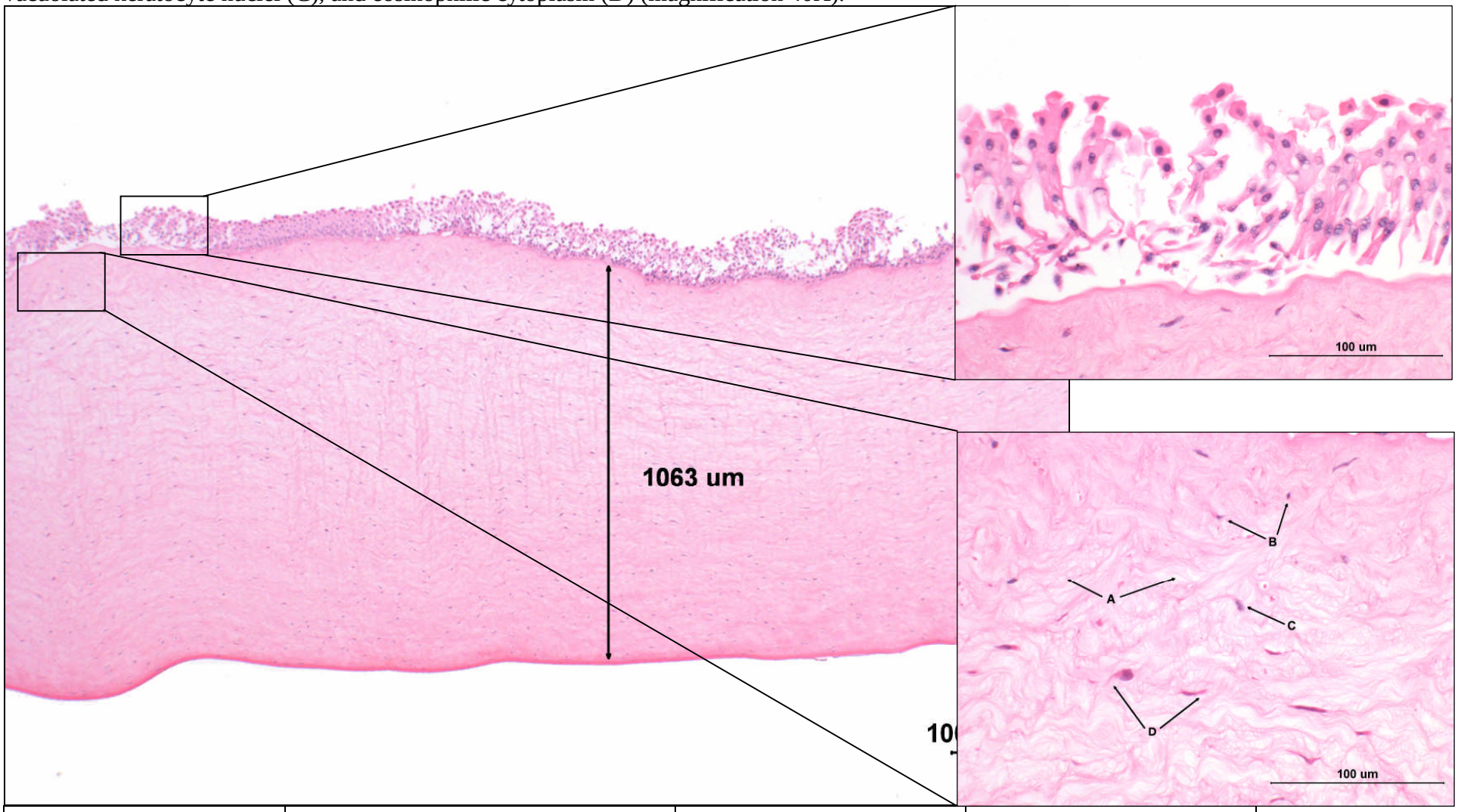

Opacity = 7	Permeability = 1.642	*In Vitro* Score = 31.6	pH = 3.5

06AG30 (60-80% ETOH), neat, 3-minute exposure, 120-minute post-exposure (8/15/06) – Full thickness (magnification 4X). Upper right – Epithelium with hypereosinophilic squamous layer (A) and separation of the basal layer (B) (magnification 40X). Middle right –Upper stroma with expansion of the collagen matrix (A), vacuolation of keratocyte nuclei (B), and eosinophilic keratocyte cytoplasm (C) (magnification 40X). Lower right – Upper stroma with pyknotic keratocyte nuclei (magnification 40X).

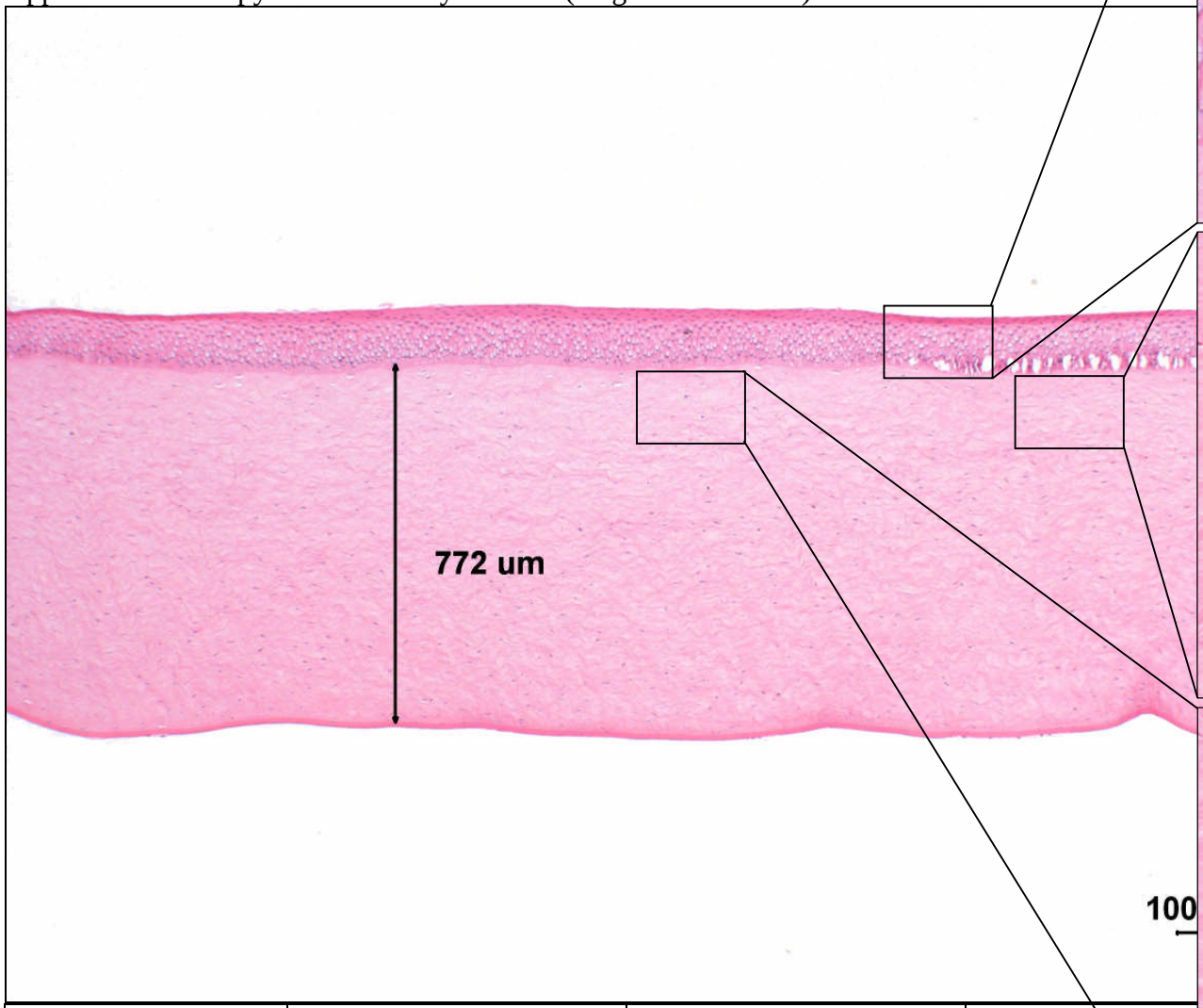

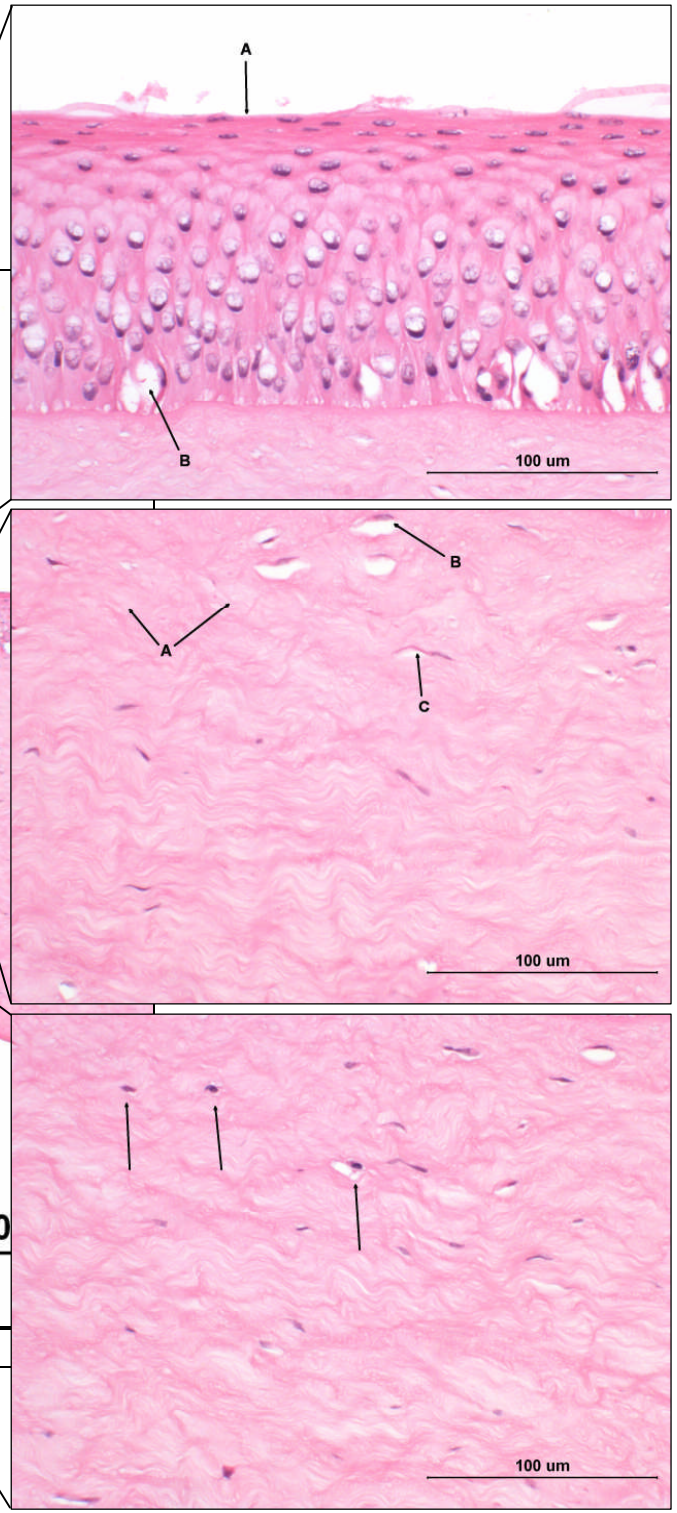

Opacity = 22.7	Permeability = 1.206	*In Vitro* Score = 40.8	pH = 6.5

06AG30 (60-80% ETOH), neat, 10-minute exposure, 120-minute post-exposure (8/15/06) – Full thickness (magnification 4X). Upper right – Epithelium with hypereosinophilic squamous layer (A) and separation of the basal layer (B) (magnification 40X). Middle right – Upper stroma with expansion of the collagen matrix (A), condensation of collagen (B), and vacuolation of keratocyte nuclei (C) (magnification 40X). Lower right – Keratocytes in lower stroma with eosinophilic cytoplasm (magnification 40X).

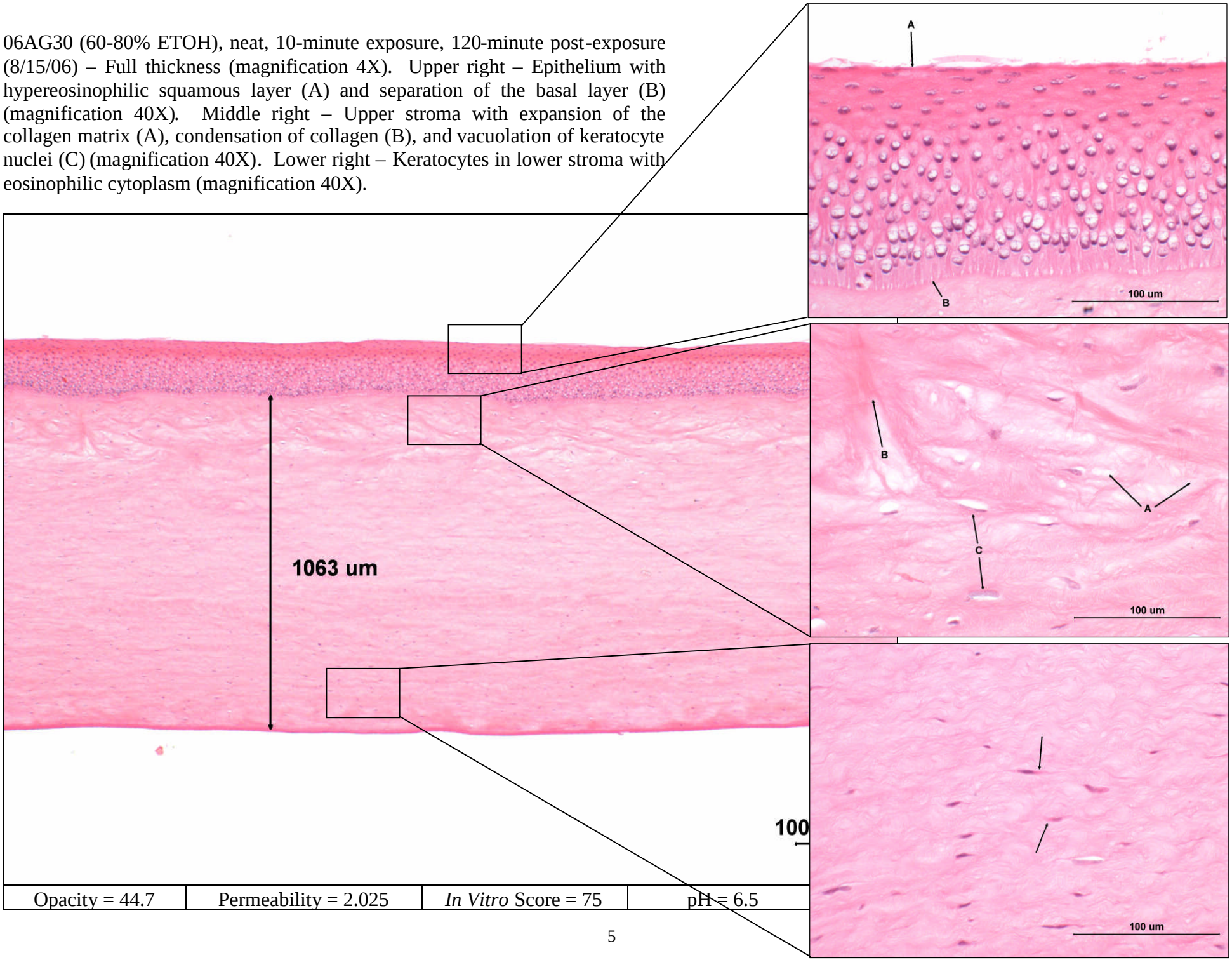

Opacity = 44.7	Permeability = 2.025	*In Vitro* Score = 75	pH = 6.5

Epithelium

06AG29, neat, 3-minute exposure, 120-minute post-exposure (8/15/06) – Epithelium with loss of the squamous layer (magnification 40X)

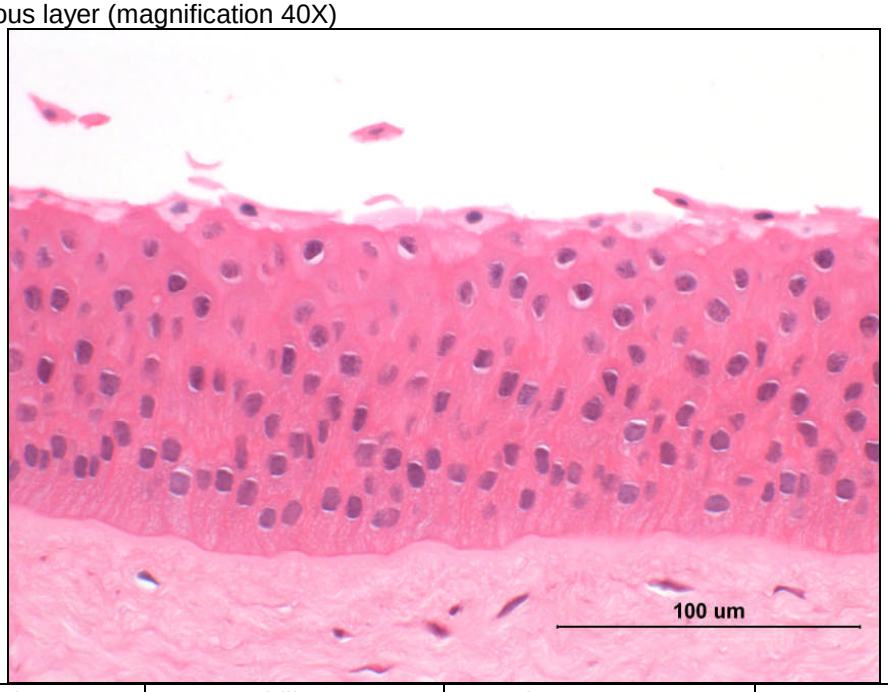

Opacity = 4.3	Permeability = 0.565	*In Vitro* Score = 12.8	pH = 3.5

06AG29, neat, 10-minute exposure, 120-minute post-exposure (8/15/06) –Epithelium with full thickness necrosis and sloughing (magnification 40X)

Opacity = 7	Permeability = 1.642	*In Vitro* Score = 31.6	pH = 3.5

06AG30 (60-80% ETOH), neat, 3-minute exposure, 120-minute post-exposure (8/15/06) – Epithelium with hypereosinophilic squamous layer (A) and separation of the basal layer (B) (magnification 40X)

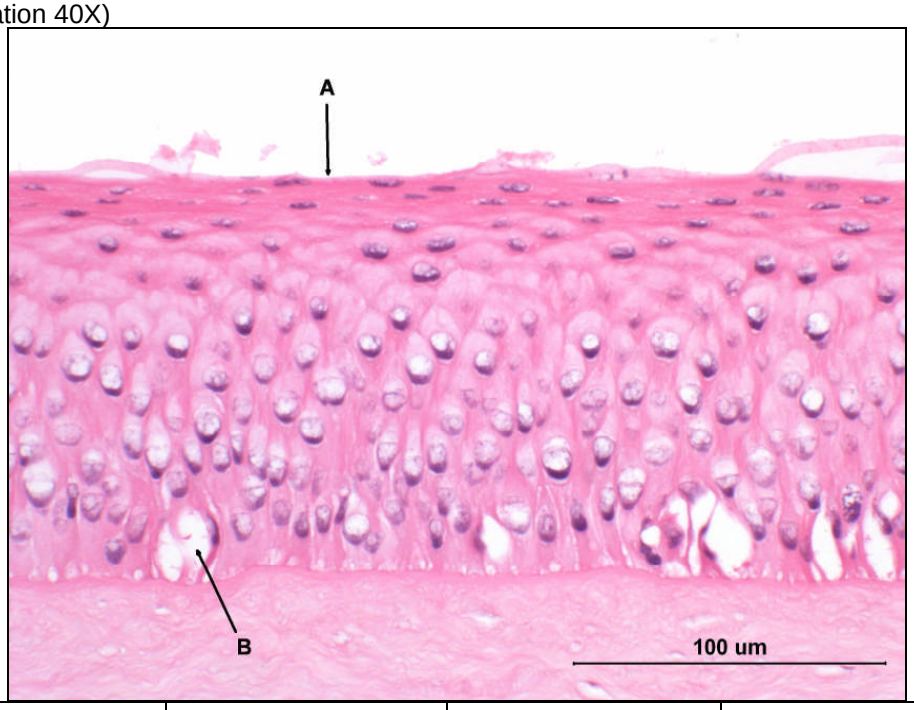

Opacity = 22.7	Permeability = 1.206	*In Vitro* Score = 40.8	pH = 6.5

06AG30 (60-80% ETOH), neat, 10-minute exposure, 120-minute post-exposure (8/15/06) – Epithelium with hypereosinophilic squamous layer (A) and separation of the basal layer (B) (magnification 40X)

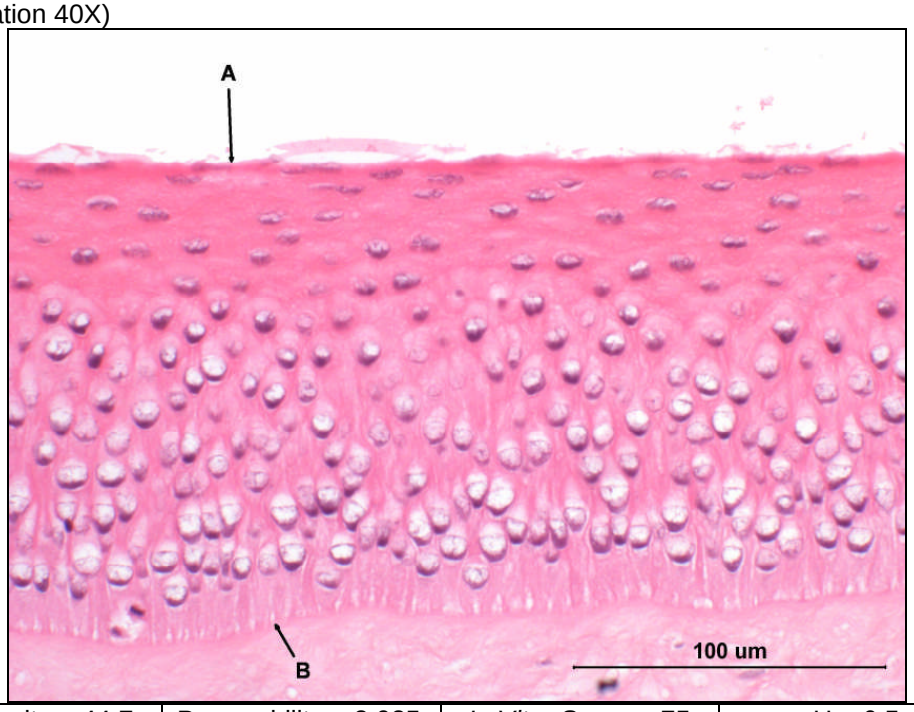

Opacity = 44.7	Permeability = 2.025	*In Vitro* Score = 75	pH = 6.5

Full Thickness

06AG29, neat, 3-minute exposure, 120-minute post-exposure (8/15/06) – Full thickness (magnification 4X)

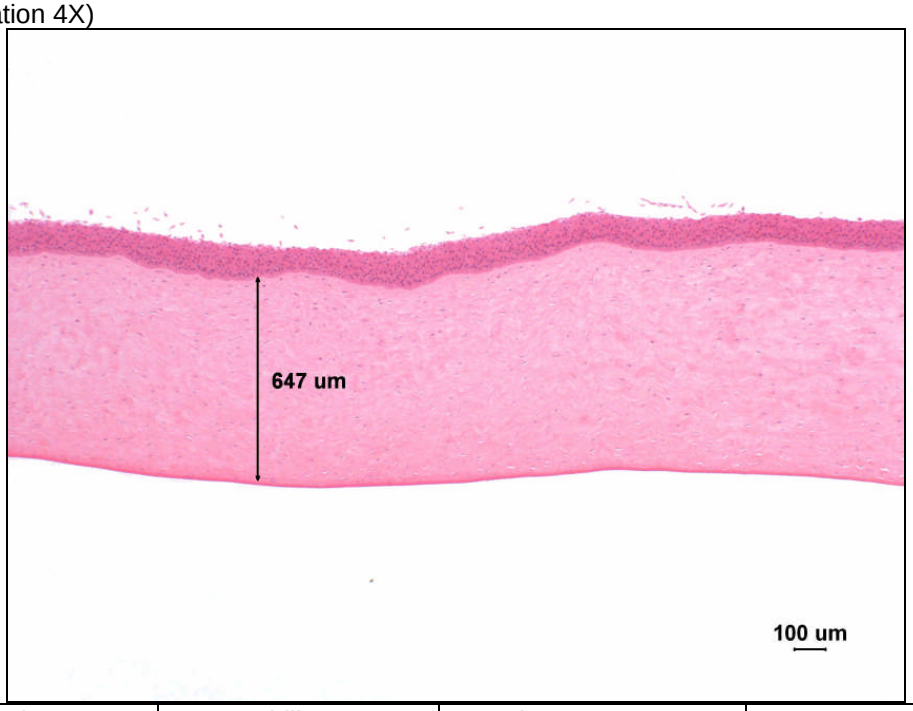

Opacity = 4.3	Permeability = 0.565	*In Vitro* Score = 12.8	pH = 3.5

06AG29, neat, 10-minute exposure, 120-minute post-exposure (8/15/06) –Full thickness (magnification 4X)

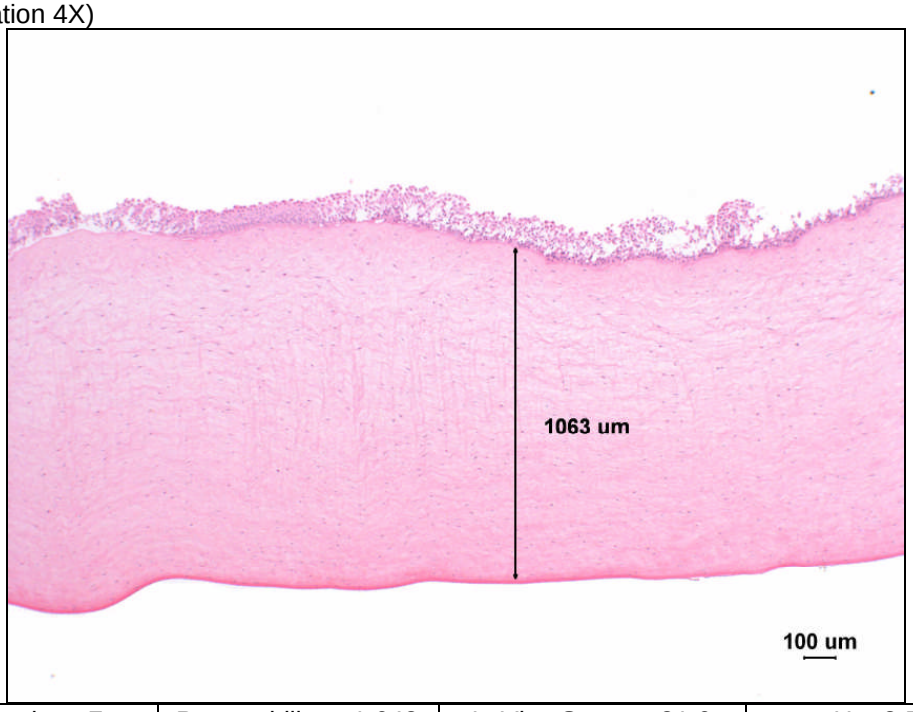

Opacity = 7	Permeability = 1.642	*In Vitro* Score = 31.6	pH = 3.5

06AG30 (60-80% ETOH), neat, 3-minute exposure, 120-minute post-exposure (8/15/06) –Full thickness (magnification 4X)



Opacity = 22.7	Permeability = 1.206	*In Vitro* Score = 40.8	pH = 6.5

06AG30 (60-80% ETOH), neat, 10-minute exposure, 120-minute post-exposure (8/15/06) – Full thickness (magnification 4X)



Opacity = 44.7	Permeability = 2.025	*In Vitro* Score = 75	pH = 6.5

Upper Stroma:

06AG29, neat, 3-minute exposure, 120-minute post-exposure (8/15/06) –Superficial stroma with expansion of the collagen matrix (A) and keratocytes with eosinophilic cytoplasm (B) (magnification 40X)

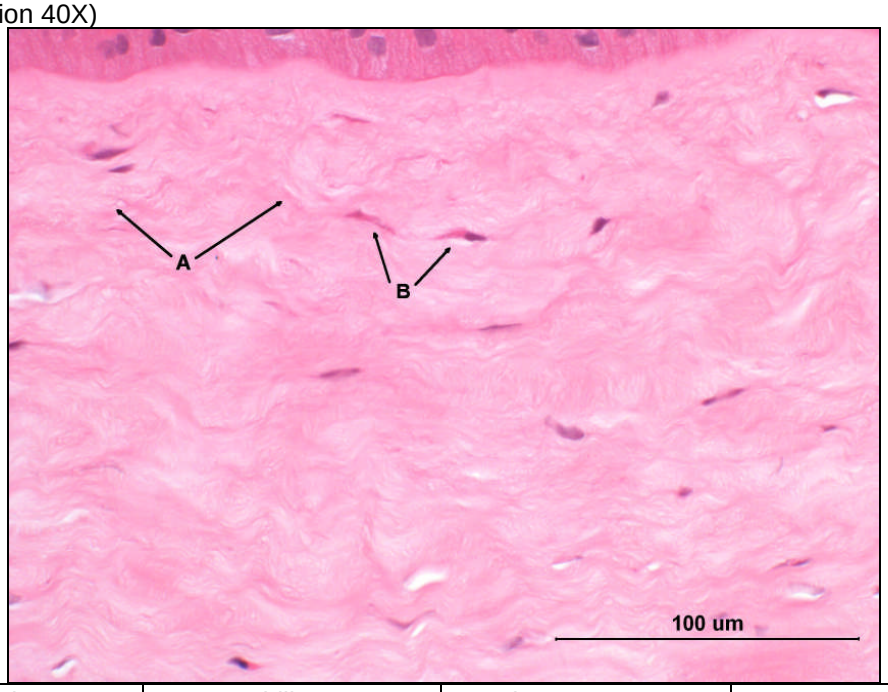

Opacity = 4.3	Permeability = 0.565	*In Vitro* Score = 12.8	pH = 3.5

06AG29, neat, 10-minute exposure, 120-minute post-exposure (8/15/06) –Upper stroma with expansion of the collagen matrix (A), nuclear pyknosis (B), vacuolated keratocyte nuclei (C), and eosinophilic cytoplasm (D) (magnification 40X)

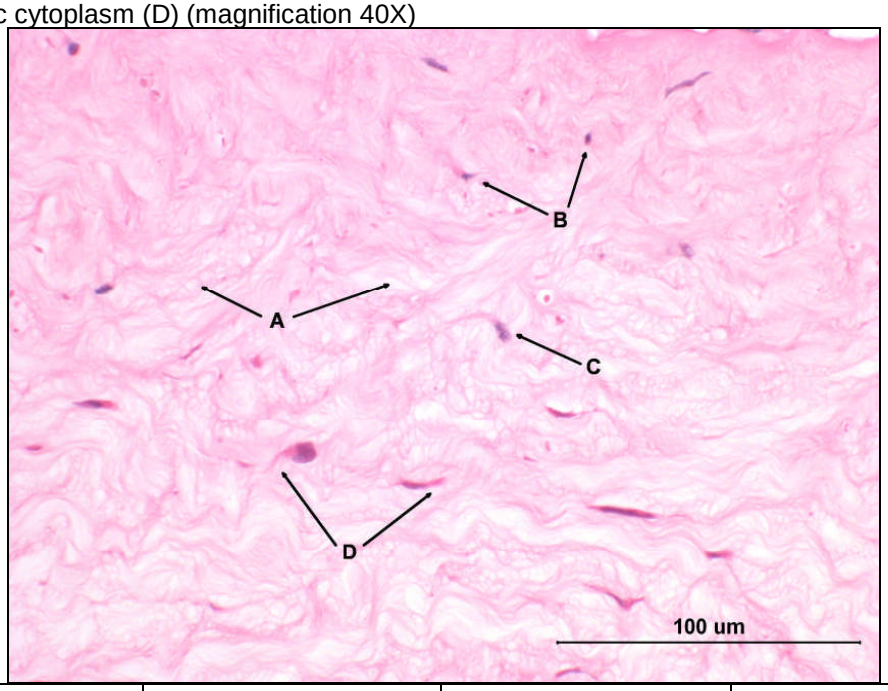

Opacity = 7	Permeability = 1.642	*In Vitro* Score = 31.6	pH = 3.5

06AG30 (60-80% ETOH), neat, 3-minute exposure, 120-minute post-exposure (8/15/06) –Upper stroma with expansion of the collagen matrix (A), vacuolation of keratocyte nuclei (B), eosinophilic keratocyte cytoplasm (C), and pyknotic keratocyte nuclei (inset) (magnification 40X)



Opacity = 22.7	Permeability = 1.206	*In Vitro* Score = 40.8	pH = 6.5

06AG30 (60-80% ETOH), neat, 10-minute exposure, 120-minute post-exposure (8/15/06) – Upper stroma with expansion of the collagen matrix (A), condensation of collagen (B), vacuolation of keratocyte nuclei (C), and pyknotic keratocyte nuclei (inset) (magnification 40X)



Opacity = 44.7	Permeability = 2.025	*In Vitro* Score = 75	pH = 6.5

Lower Stroma

06AG30 (60-80% ETOH), neat, 10-minute exposure, 120-minute post-exposure (8/15/06) – Keratocytes in lower stroma with eosinophilic cytoplasm (magnification 40X)

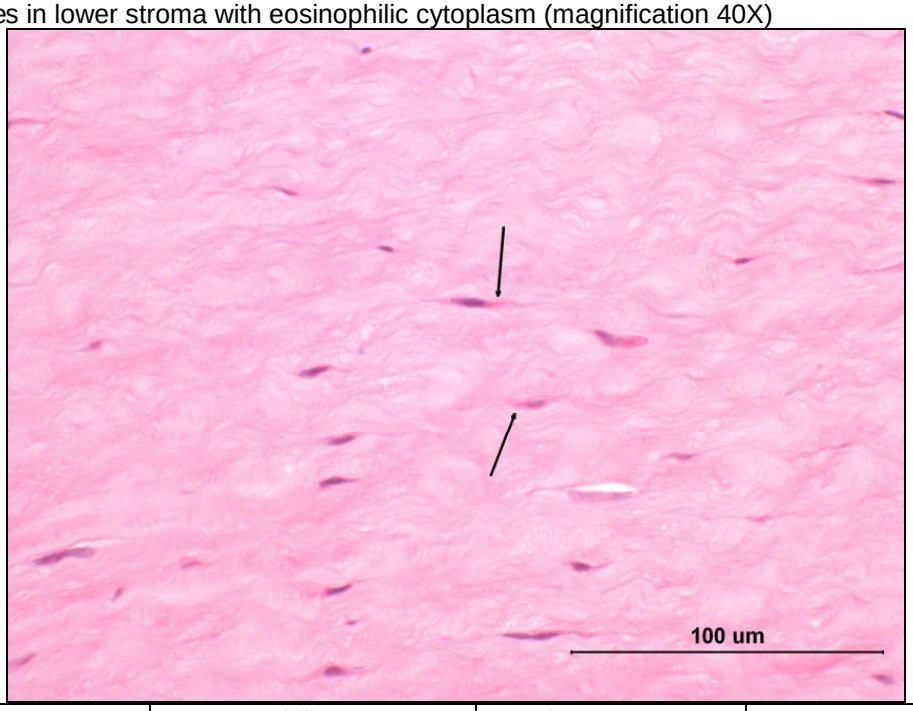

Opacity = 44.7	Permeability = 2.025	*In Vitro* Score = 75	pH = 6.5